

---

# Papillary carcinoma in the thyroglossal duct cyst

Nalan Alev Canbolat<sup>1</sup>, Tarik Gandi Cincin<sup>2</sup>, Serdar Yanik<sup>3</sup>, Ayse Neslin Akkoca<sup>4</sup>,  
Aysegul Kaynar<sup>3</sup>

<sup>1</sup>Iskenderun State Hospital, Department of Otorhinolaryngology, Hatay, Turkey

<sup>2</sup>Iskenderun State Hospital, Department of General Surgery, Hatay, Turkey

<sup>3</sup>Iskenderun State Hospital, Department of Patology, Hatay, Turkey

<sup>4</sup>Iskenderun State Hospital, Department of Family Medicine, Hatay, Turkey

## Email address:

ayseneslinoguzhan@hotmail.com (A. N. Akkoca)

## To cite this article:

Nalan Alev Canbolat, Tarik Gandi Cincin, Serdar Yanik, Ayse Neslin Akkoca, Aysegül Kaynar. Papillary Carcinoma in the Thyroglossal Duct Cyst. *Journal of Surgery*. Vol. 2, No. 5, 2014, pp. 63-64. doi: 10.11648/j.js.20140205.11

---

**Abstract:** Aim: The most common congenital neck masses are thyroglossal duct cysts (TDC). They are often benign. 1% may become malignant. Although rare; the most common malignant pathology of them are thyroid papillary carcinoma. Therefore we wanted to share this case considering that is important.

**Keywords:** Thyroglossal Duct Cyst, Thyroid Gland, Papillary Carcinoma

---

## 1. Introduction

Thyroglossal Duct Cyst is the most common developmental anomalies of the thyroid gland (1). The thyroid gland in the embryo, down towards from foramen cecum to the back of the thyroid cartilage and leaves a epithelial channel (thyroglossal duct). This channel begin to decline In the 5.-10. weeks. If the channel does not close thyroglossal cyst and fistula occurs. In more than 60% of thyroglossal duct cysts there is a thyroid tissue in the cyst wall. Thyroglossal duct cysts Carcinoma is seen in approximately 1% of thyroglossal duct cysts cases. The most common type of thyroglossal duct cysts carcinomas, are papillary carcinoma with 85% ratio and follows as papillary-follicular with 8% ratio and the squamous cell carcinoma with 6% ratio (2).

## 2. Case Report

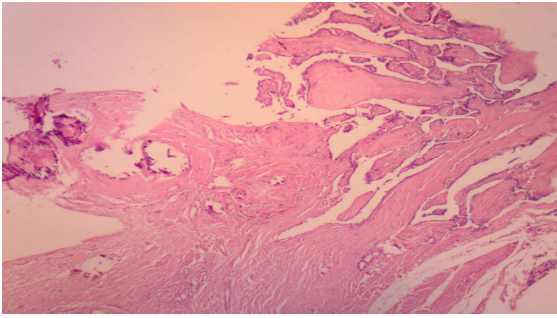
25 year old female patient was admitted to our clinic with complaints of palpable nodule at midline of the neck. She said that, it appeared suddenly about 2 years ago and grew with time but she had not any complaint of the mass such as pain, redness or wound discharge. In the case she had no familial history, dyspnea, dysphagia, hoarseness. The patient also had no smoking habits, alcohol use, history of radiation therapy.

On physical examination, moving mass of medium hardness, mobile at swallowing with 3cm in size was determined in the

midline neck. The neck ultrasonography (USG) and computed tomography (CT) was reported as a 2.8 cm in size cystic mass (TDC). The largest 4 mm in diameter calcification foci were present in the cyst. There was no cervical lymphadenopathy. No pathology was observed in the thyroid gland and in bone tissue at CT . Thyroid USG and scintigraphy performed in and any pathology was detected in the thyroid gland. Thyroid function tests were within normal limits.

The patient underwent cistrunk operation. During the operation, passing platysma muscles and strep muscles it has been reached to the mass . The mass was dissected from the thyroid cartilage to hyoid bone and the corpus of the hyoid bone and the total mass was excised with. Irregular shaped biopsy material was removed in 3-2-0.8 measures. Biopsy material was evaluated TDC with PC (Figure 1). Patient was discharged on postoperative day 2 as there was no complications. In the postoperative period thyroid function tests were determined to be normal. Results were evaluated with the patient. The patient informed that PC may be multicentric and there can be microcarcinoma in the thyroid gland so thyroidectomy was recommended. After obtaining approval from the patient underwent bilateral total thyroidectomy. In the thyroid gland, the examination showed normal histology. Postoperative follow-up of patients no pathology was detected in thyroid USG. Postoperative follow-up thyroglobulin levels were measured. Thyroid scintigraphy was performed. During the 2 years of postoperative no clinical and radiological recurrence was

detected in our patient.



**Figure 1.** Thyroglossal cyst in one area of; around the fibrovascular cores papillary configuration showing the consecutive bearish, pseudoinclusions, Groove, nuclear features, together Psammom bodies, monitoring of papillary carcinoma of the 4 \* 10 luke magnification. Hematoxylin-eosin staining.

### 3. Discussion

Thyroid uses the thyroglossal duct, while migrating from the pharynx base to the neck in embryonic life. This channel loses over time as it has no functionality. However, some parts of the channel may remain persistent and continuing of secretion of duct cells may result to cysts (1). TDC is more than 2 times of branchial cleft cyst. 90% of TDC settles midline neck, some settles paramedial. Paramedial settled ones are usually on the left as found in our (1). TDC usually sizes 1-5 cm. It can include mucoid or gelatinous material. The thyroid tissue does not always occur in microscopy. It may be pseudostratified columnar epithelium, cuboidal or stratified squamous epithelium (2). In our case, the lesion was 3 cm in diameter and contained serous material and thyroid follicular epithelium was present in the wall microscopic examination.

The cancer development on the basis of TDC often occurs in 4th decade of life. The majority of cases are diagnosed after surgical removal of the lesion (3). In TDC, two types have been reported: develops from the thyroid gland elements and squamous cell epithelium. The most common pathology is PC (85%), follicular carcinoma (15%) and squamous cell carcinoma (6%) are seen less frequently (4,5). In this case, the preoperative pathology was not detected suggesting PC. The diagnosis was made by pathologic examination of the cyst excision. PC developing from TDC does not show a different trend from a benign thyroglossal cyst in clinic. Although it is very rare, but pain, hoarseness, a sudden increase in size, weight loss, regional lymphadenopathy can be seen and should suggest the formation of malignancy (5). It is necessary to clarify whether the PC is primary. There should be epithelium wall of the cyst, normal thyroid tissue in or near to the cyst and thyroid histopathological examination should be normal (5).

In these cases, there is no consensus on about thyroidectomy (6). Some authors favor surgical removal of the cyst and some others are of the opinion that cyst excision and after follow up is sufficient. The invasion of the cyst wall has been proposed as a criterion for thyroidectomy and even neck dissection (6,7). Minimum intervention in the treatment of TDC carcinoma must be the cystectomy (excision of the

hyoid with TDC) and there is consensus on this issue (8). However, some authors argue that in addition to cystectomy total thyroidectomy, radioactive iodine therapy and TSH suppression should be applied because with high probability of simultaneous carcinoma focus in the thyroid gland and of multifocal possibility of the carcinoma (9). 5 and 10 year survival percentages of TDC carcinomas are 100% and is 95.6% (6). Also adding the total thyroidectomy to cystectomy operation was reported as having no significant effect on results (6,10).

We did bilateral total thyroidectomy in our case as we think that PC can occur as a multicentric, although rare. It is complained in the literature that case number is so small and long-term follow-up is not enough so not enough information about the prognosis. However, some sources treated thyroglossal cyst carcinoma as the primary thyroid primary and also think that high chance of cure in younger patients with well-differentiated carcinoma. However, as in all children with thyroid neoplasms in young patients need careful follow-up reveals that the long-term.

### References

- [1] Antonio, Pieter J. Slootweg Pathology of Head and Neck, Thyroglossal Duct Cyst and Ectopic Thyroid, Springer Germany; 1 edition. 2006; p.268.)
- [2] Yuri E. Nikiforov, Paul W. Biddinger, Lester D.R. Thompson. Thyroglossal duct cyst. Embryology and Developmental Lesions. In: diagnostic pathology and molecular genetics of the thyroid. Philadelphia, JB Lippincott. 2009; p.18-20
- [3] Torvicia A, Polliand C, Zioli M, Dufour F, Champault G, Barrat C., Papillary carcinoma of the thyroglossal duct cyst; report of two cases, Rom J Morphol Embryol 2010, 51:775-777.
- [4] Wigley TL, Chonkich GD, Wat BY. Papillary Duct Carcinoma arising in a thyroglossal duct cyst. Otolaryngology H&N surgery 1997; 116:3:386-388
- [5] Martin-Perez E, Larranaga E, Maron C, Monje F.: Primary Papillary carcinoma arising in the thyroglossal duct cyst. Eur J Surgery 1997; 163:143-145
- [6] Patel SG, Escrig M, Shaha AR, Singh B, Shah JP. Management of well-differentiated thyroid carcinoma presenting within a thyroglossal duct cyst. J Surg Oncol 2002; 79:134-9)
- [7] Altuntaş E, Elagöz Ş, Thyroglossal kanal kistinde papiller karsinoma: İki olgu sunumu ve literatürün gözden geçirilmesi (Papillary carcinoma in thyroglossal duct cyst: report of two cases and review of the literature). Cumhuriyet Tıp Dergisi 2012; 34:107-12
- [8] Motamed M, McGlashan JA. Thyroglossal duct carcinoma. Curr Opin Otolaryngol Head Neck Surg 2004; 12: 106-9)
- [9] Pribitkin EA, Friedman O. Papillary carcinoma in a thyroglossal duct remnant. Arch Otolaryngol Head Neck Surg 2002; 128:461-2)
- [10] Balalaa N, Megahed M, Ashari MA, Branicki F, thyroglossal duct cyst papillary carcinoma case report oncol. 2011; 4: 39-43.