

# Role of MRI Fistulography with Gadopentate Enhancement in Assessment of Complex Anal Fistulas and Improving Surgical Outcomes

Mahmoud Abdelnaby, Sameh Hany Emile<sup>\*</sup>, Ahmad Sakr, Alaa Magdy, ElYamani Fouda, Ahmed Abdel Mawla

Colorectal Surgery Unit, General Surgery Department, Mansoura Faculty of Medicine, Mansoura University, Mansoura City, Egypt

## Email address:

abdelshafymahmoud@ymail.com (M. Abdelnaby), sameh200@hotmail.com (S. H. Emile), Ahmadsakr1987@gmail.com (A. Sakr), alaamagdy72@yahoo.com (A. Magdy), mani\_fouda@yahoo.com (ElY. Fouda), Draahmedabdelmawla71@gmail.com (A. Abdel Mawla)

<sup>\*</sup>Corresponding author

## To cite this article:

Mahmoud Abdelnaby, Sameh Hany Emile, Ahmad Sakr, Alaa Magdy, ElYamani Fouda, Ahmed Abdel Mawla. Role of MRI Fistulography with Gadopentate Enhancement in Assessment of Complex Anal Fistulas and Improving Surgical Outcomes. *Journal of Surgery*. Vol. 5, No. 2, 2017, pp. 22-27. doi: 10.11648/j.js.20170502.13

**Received:** March 11, 2017; **Accepted:** March 20, 2017; **Published:** April 10, 2017

---

**Abstract:** Preoperative assessment of complex fistula-in-ano (FIA) is crucial for decision making. Magnetic resonance imaging (MRI) has been used for assessment of perianal sepsis with various protocols and methods. The aim of the present study was to assess the concordance between MRI fistulography with gadopentate enhancement and the intraoperative surgical findings, and to study the impact of preoperative assessment with MRI on surgical outcomes including fistula recurrence and fecal incontinence (FI). Patients with complex and high FIA who were investigated by MRI fistulography preoperatively were reviewed. The concordance between the findings of MRI and the intraoperative findings on examination under anesthesia (EUA) was made using Kappa coefficient test. The accuracy and sensitivity of MRI were calculated regarding detection of the internal opening, primary and secondary fistula tracts. 95 patients (82% males) were included in the study. MRI fistulography had an accuracy of 89.4%, 96.8%, 96.8%, 98%, and 98% in detection of the internal opening, number of tracts, position of primary tract, secondary extensions, and presence of abscess cavities, respectively. Overall, there was very good concordance between MRI and EUA regarding the examined parameters ( $k=$  0.847, 0.937, 0.908, 0.953, 0.957), respectively. Fistula recurrence and minor FI were recorded in 4.2% and 14.7% of patients. MRI fistulography is an effective diagnostic modality for the preoperative assessment of FIA. MRI had excellent accuracy and sensitivity in detection of the internal opening, primary tract, and secondary extensions of anal fistula with very good concordance with the intraoperative findings.

**Keywords:** MRI, Fistulography, Anal Fistula, Complex, Assessment, Outcomes

---

## 1. Introduction

Fistula-in-ano (FIA) is a common anorectal disorder with an estimated prevalence of around 1 in 10,000 individuals [1]. FIA is defined as an abnormal communication between the epithelialized surface of the anal canal and perianal skin. In the majority of the cases FIA is attributed to an inflammatory process arising from a cryptoglandular perirectal abscess.

While the standard assessment of patients with anal fistulas is examination under anesthesia (EUA) [2], preoperative imaging is usually warranted to define the site

and full extent of the disease. Fistulography, endorectal ultrasonography (ERUS), and magnetic resonance imaging (MRI) have been used to establish the relation between the fistula tract and the anal sphincters and other related structures.

Inadequate assessment of FIA may result in converting simple fistulas into a more complex entity. Moreover, failure to appreciate complex ramifications of FIA can result in recurrent sepsis [3, 4]. Missing secondary tract extensions at surgery is usually the principal cause of recurrence, hence adequate surgery is mandatory in more extensive disease [5].

MRI has been recognized as an accurate diagnostic tool for

the assessment of FIA [6]. MRI has been shown to reduce recurrent disease and, therefore reoperation rates. It does not only help demonstrate the disease extension accurately, but also serves to predict prognosis and make surgical decisions [7, 8]. In patients with Crohn's disease recurrence could be due to inadequate medical treatment rather than missed secondary extensions, therefore MRI can be used for monitoring therapy and predicting prognosis in patients with Crohn's disease [9].

A variety of MR sequences have been proposed for assessment of FIA with varying results [10]. MRI with body or external phased array pelvic receiver coils can be used to assess both simple and complex fistulas. The development of an endoanal receiver coil has allowed high resolution MRI of the anal sphincter complex with detailed delineation of various muscle layers [11].

In addition to MRI, ERUS is also used for the primary assessment of complex and high FIA. Kołodziejczak et al [12] described 3D-ERUS as an accurate and reproducible modality for the assessment of type and height of anal fistulae with overall accuracy 91% for fistula type and 92% for fistula height. On the other hand, both modalities were reported to have comparable sensitivity, yet with higher specificity in favor of MRI [13].

The aim of the present study was to assess the concordance between MRI fistulography with gadopentate enhancement and the intraoperative surgical finding, and to study the impact of preoperative assessment with MRI on surgical outcomes including fistula recurrence and fecal incontinence (FI).

## 2. Patient and Methods

Prospective data of patients who were treated for high complex FIA in Mansoura colorectal surgery center (private center) between January 2015 and December 2016 were reviewed. Ethical approval for the study was obtained from the institutional review board of Mansoura Faculty of Medicine.

### 2.1. Eligibility Criteria

Adult patients of both genders presented with complex FIA were included in this study. Complex anal fistulas included high trans-sphincteric, horse-shoe, recurrent, multiple branching and high fistulas with supralelevator extension.

We excluded patients aging below 16 years, and patients with FIA secondary to inflammatory bowel diseases (IBDs), tuberculosis, sexually transmitted diseases, or malignancy. Patients with preoperative FI, and patients with other anorectal pathology such as hemorrhoids and rectal prolapse were also excluded from the study.

### 2.2. Preoperative Assessment

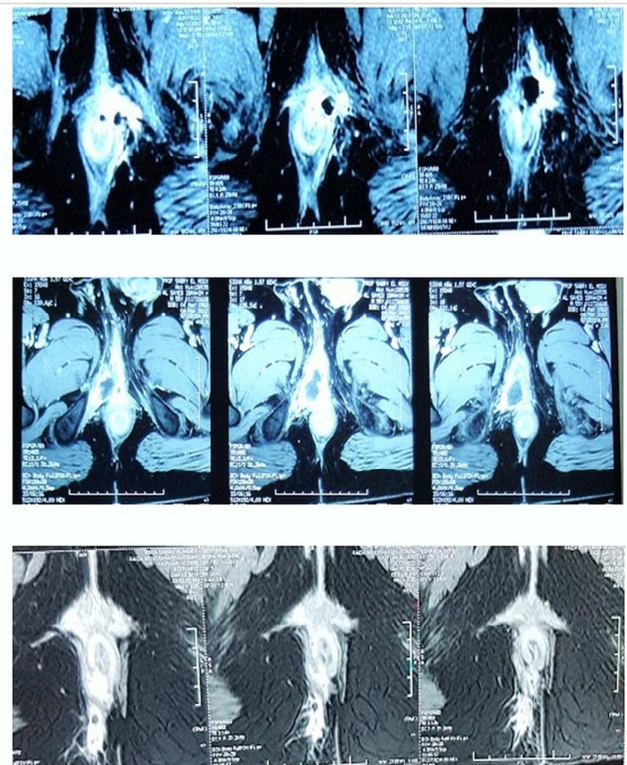
Detailed history was taken from all patients regarding the type, onset, and duration of complaint, other related

symptoms, previous investigations or treatments received for the current complaint, and associated medical comorbidities. Preoperative continence state was evaluated by Wexner continence score [14]. Patients were then investigated by MRI fistulography for assessment of the type and extension of anal fistula, afterwards patients received surgical treatment of the anal fistula within 1-2 weeks after MRI examination.

### 2.3. Technique of MRI

MR imaging was performed using a 1.5 tesla scanner (General Electric) HDe signa GEHC scanner using anterior array 8 channel coil, firstly non-contrast T1 FSE axial and coronal oblique study was done TR/TE, 600/10 ms, with matrix 512 x 512, FOV 28 x 28 cm<sup>2</sup>, NEX=4 and slice thickness about 4 mm and 0.5 mm inter slice gapping were obtained, then post-IV-contrast FSPGR images in same planes, slice thickness & inter-slice gapping with Flip angle = 80 degree, TR/TE, 435/3.1, matrix 512 x 192, FOV 26 x 26 cm<sup>2</sup>, NEX=3 study was done using gadopentat emeglumine 0.5 mL/kg (0.1 mmol/kg) body weight with maximum dose of 10 mL was administrated (using 20 to 22 G venous cannula) as an intravenous bolus injection at a flow rate of approximately 2 mL/s, the total time examination 16 to 18 minutes.

### 2.4. Image Evaluation



**Figure 1.** MRI fistulography Displaying trans-sphincteric anal fistula (upper row), anal fistula associated with abscess cavity (middle row), and intersphincteric anal fistula (lower row).

MRI images were evaluated by a specialized radiologist with experience in reading pelvic MRI. The radiologist was

aware about the clinical suspicion of perianal sepsis. Images were evaluated for the presence and site of fistula tracks, abscesses, internal openings, horseshoe, or other secondary extensions of the primary tract (Figure 1). Anal fistula was classified according to St James University hospital MRI-based grading system [15] into 0, normal appearance; 1, simple linear intersphincteric fistula; 2, intersphincteric fistula with intersphincteric abscess or secondary track; 3, trans-sphincteric fistula; 4, trans-sphincteric fistula with abscess or secondary track within the ischioanal or ischioanal fossa; 5, supralelevator and translevator disease.

### 2.5. Surgery

Surgery was performed by a single colorectal surgeon who is experienced in fistula surgery. Surgery was conducted in the modified lithotomy position with the patient under general or spinal anesthesia. The site of fistula tracks, external and internal openings, and horseshoe or other secondary extensions of the primary tract as well as the presence and location of any abscess were recorded. The operating surgeon was aware of the MRI findings preoperatively and used the findings of MRI imaging as a guide during surgery. The intraoperative findings were compared to those of preoperative MRI fistulography. Coring fistulectomy of the superficial part of the tract with placement of draining silk around the deep part of the tract and the involved anal sphincter complex was performed for all patients. Silk seton was elected to be performed since it has conferred acceptably low recurrence and incontinence rates according to our experience [16].

### 2.6. Data Collection

The following data were extracted from patients' records:

- Patients' demographics as age, gender, associated comorbidities, and Wexner continence score.
- Type of FIA and position of external and internal openings as revealed by clinical examination.
- Characteristics of FIA revealed by MRI fistulography and EUA including position of the internal opening, position of the primary track, and presence of secondary extensions as supralelevator extension or horse-shoe fistula.

### 2.7. Statistical Analysis

Statistical analysis was conducted using SPSS version 23 program (IBM Corp; Bristol, UK) under Microsoft Windows. Continuous variables were described as mean and standard deviation (SD) while categorical variables were described as median and normal range. Student t-test was used to analyze the continuous data and Fisher's exact test or Chi square test was used to process categorical data. P values less than 0.05 were considered significant.

The concordance between MRI fistulography (index test) and EUA (reference standard) regarding the position of internal opening, position of primary tract, and presence of secondary extensions was assessed using Cohen's kappa

coefficient (k). Agreement between ERUS and EUA according to kappa was classified as perfect (k=1), very good (k=0.81–0.99); good (k=0.61–0.80), moderate (k=0.41–0.60), fair (k=0.21–0.40), and poor (k=0.20 or less) [17]. Sensitivity, specificity, positive predictive value (PPV) and negative predictive value (NPV) of MRI fistulography were calculated.

## 3. Results

### 3.1. Patients' Characteristics

Ninety-five patients with complex FIA were studied. Patients were 78 (82%) males and 17 (18%) females of a mean age of  $39 \pm 11.7$  (16-68) years. Seventy-two (75.7%) patients presented with primary anal fistula and 23 (24.3%) patients presented with recurrent FIA after previous surgery.

The external opening of the anal fistula was anterior to the transverse anal line in 32 (33.7%) patients, posterior in 35 (36.8%) patients, lateral in 18 (19%) patients, whereas 10 (10.5%) patients had multiple external openings.

### 3.2. Utility of MRI Fistulography in Detecting the Site of the Internal Opening

The position of the internal opening according to MRI Vs EUA was as follows: anterior (31 Vs 32), posterior (29 Vs 35), lateral (18 Vs 18), multiple (9 Vs 9). In eight (8.4%) patients, MRI could not identify the site of the internal opening. The internal opening was accurately localized by MRI in 85 of the remaining 87 patients.

The overall accuracy of MRI in detecting the site of the internal opening was 89.4% (95%CI: 81.7- 94.1%) with a sensitivity rate of 91.4% (95%CI: 83.7- 96.2%) and PPV of 97.7% (95%CI: 97.5- 97.8%). There was very good concordance between MRI fistulography and intraoperative findings regarding the site of the internal opening with linear weighted kappa of 0.847 (95% CI: 0.75- 0.94)

### 3.3. Utility of MRI Fistulography in Detecting the Number of Fistula Tracts

The number of fistula tracts according to MRI Vs EUA was as follows: single (68 Vs 68), multiple (13 Vs 11), and horse-shoe fistula (14 Vs 16). The number of fistula tracts was correctly identified by MRI fistulography in 92 (96.8%) patients [95%CI: 91.1- 98.9%] with a sensitivity rate of 100% (95%CI: 96-100%) and PPV of 96.8% (95%CI: 91-99.3%). There was very good concordance between MRI fistulography and intraoperative findings regarding the number of the fistula tracts with linear weighted kappa of 0.937 (95%CI: 0.86- 1).

### 3.4. Utility of MRI Fistulography in Detecting the Position of the Primary Fistula Tract

According to the MRI-based grading of FIA, there were six fistulas of grade 2, 47 of grade 3, 33 of grade 4, and nine fistulas of grade 5.

The position of primary fistula tract according to MRI Vs EUA was as follows: trans-sphincteric (75 Vs 72), intersphincteric (19 Vs 22), and extra-sphincteric (1 Vs 1). The position of the primary tract was correctly identified by MRI fistulography in 92 (96.8%) patients [95%CI: 91.1-98.9%] with a sensitivity rate of 100% (95%CI: 96-100%) and PPV of 96.8% (95%CI: 91- 99.3%). There was very good concordance between MRI fistulography and intraoperative findings regarding the position of the fistula tract with linear weighted kappa of 0.908 (95%CI: 0.806- 1).

### 3.5. Utility of MRI Fistulography in Detecting Secondary Extensions

MRI fistulography detected secondary fistula branches in 33 patients, one of which did not have secondary branches on EUA. On the other hand, in 62 patients MRI noted no secondary extensions while one patient had a branched fistula on EUA.

Overall, secondary fistula extensions were correctly identified by MRI fistulography in 93 (98%) patients [95%CI: 92.6- 99.4%] with a sensitivity rate of 97% (95%CI: 84.2-99.9%), specificity of 98.3% (95%CI: 91.3- 99.9%),

PPV of 97% (95%CI: 82- 99.5%), and NPV of 98.4% (95%CI: 89.8-99.7%).

There was very good concordance between MRI fistulography and intraoperative findings regarding the detection of secondary fistula extensions with linear weighted kappa of 0.953 (95%CI: 0.89- 1).

### 3.6. Utility of MRI Fistulography in Detecting Abscess Cavities

MRI fistulography detected abscess cavities in 46 patients, two of which did not have secondary branches on EUA. On the other hand, no abscess cavity was noted in 49 patients by both MRI and EUA. The presence of abscess cavity was accurately determined by MRI in 93 (98%) patients [95%CI: 92.6- 99.4%] with sensitivity rate of 100% (95%CI: 92- 100%), specificity of 96.1% (95%CI: 86.5- 99.5%), PPV of 95.6% (85- 99%), and NPV of 100%.

There was very good concordance between MRI fistulography and intraoperative findings regarding the detection of abscess cavities with linear weighted kappa of 0.957 (95%CI: 0.91- 1). Summary of the diagnostic utility of MRI fistulography is presented in table 1.

*Table 1. Summary of the accuracy, sensitivity, and concordance of MRI fistulography with intraoperative surgical findings.*

Variable	Accuracy (%)	Sensitivity (%)	PPV (%)	Concordance
Site of internal opening	89.4	91.4	97.7	0.847 (95% CI: 0.75- 0.94)
Number of tracks	96.8	100	96.8	0.937 (95%CI: 0.86- 1)
Position of primary tract	96.8	100	96.8	0.908 (95%CI: 0.806- 1)
Presence of secondary tracts	98	97	97	0.953 (95%CI: 0.89- 1)
Presence of abscess cavity	98	100	95.6	0.957 (95%CI: 0.91- 1)

### 3.7. Outcome of Fistula Surgery

Fistula recurrence was recorded in four (4.2%) patients after removal of seton. Minor FI was noted in 14 (14.7%) patients with median Wexner score of 3 (range, 2-6).

## 4. Discussion

Complex and high FIA still represent a challenging problem for general and colorectal surgeons. The problem with this type of anal fistula is the complexity of the tract, usual presence of secondary extensions or associated abscesses, and the intimate relation with the anal sphincters. In order to achieve complete cure, the primary fistula tract and its ramifications should be properly identified and excised, yet without compromising the integrity of the anal sphincter complex. To this end, preoperative assessment by various imaging modalities, including ERUS and MRI fistulography, was devised.

Many investigators considered MRI the gold standard for preoperative assessment of anal fistulas suggesting that MRI, if properly performed, can replace EUA [18, 19]. Other surgeons endorsed the use of ERUS for evaluation of FIA before surgery proposing that the results of hydrogen peroxide-enhanced ERUS are comparable to MRI [20]. The advent of three dimensional technology made ERUS a more

accurate and reproducible tool in determining the type and height of anal fistulae as reported in a recent study [12]. Although ERUS can effectively assess some types of complex FIA, MRI is generally deemed superior for the appraisal of more complex anal fistulas [21]. The key advantages of MRI include being well tolerated without the need for previous preparation [19], the high spatial resolution of the image, and possibility of multiplanar imaging [22].

The indications for MRI in the assessment of perianal sepsis include 1. Confirming the presence of anal fistula in the cases where the external orifice is healed, yet the fistula track might be still persistent; 2. Demonstrating the pathologic anatomy of the primary fistula tract and its secondary branches to help surgical planning; 3. Follow-up of medical treatment in secondary FIA, namely to Crohn's disease [19, 23].

In the present study, 95 patients with complex and high FIA were evaluated by MRI fistulography preoperatively. Around one-quarter of the patients had previous surgery for anal fistula implying the intricacy of their condition. T2-Weighted image sequence was applied with the use of intravenous infusion of gadopentat emeglumine as a contrast medium. The vast majority (93.6%) of FIA had a high grade (3-5) according to the MRI-based grading which correlates with less favorable outcomes [24]; this may explain the relatively high rate of FI postoperatively.

There exist several protocols for performing MRI for the

evaluation of FIA, however, there is no consensus on the optimal protocol yet. These protocols can be broadly categorized either MRI using coil or MRI fistulography [19]. The former entails the use of endorectal or superficial coil which attains the highest spatial resolution, yet with restriction of the examined field [25]. The latter involves injection of contrast medium either directly into the fistula tract or indirectly in the blood stream akin to the present study [10].

The MRI protocol employed in the current study had an accuracy rate of around 90% in detecting the internal opening and over 95% in depicting the primary and secondary tracts and abscess cavities. These accuracy rates are better than what West and coworkers [20] have reported on the use of endoanal MRI for assessment of FIA. We also found the concordance between MRI and EUA near perfect, in line with Lo Re *et al.* [26] who reported a perfect agreement between MRI and operative findings, however the authors applied different MRI protocol (STRI sequence) and studied a fewer number of patients than our study.

MRI fistulography using gadopentat managed to identify the internal opening accurately in 85 out of the 95 patients examined, in accord with another report that also applied MRI fistulography but using direct injection of mixture of gadolinium and hydrogen peroxide in the fistula tract [27]. MRI fistulography had a very high sensitivity for all the investigated parameters, particularly the detection of the primary track and abscess cavities. In concordance with our findings, Beets-Tan and colleagues [28] reported similar sensitivity rates of MRI in detecting the internal opening (96%) and in detection of the fistula tracts (100%). On the other hand, Maier *et al.* [21] reported lower sensitivity (84%) of MRI in evaluation of FIA than the present study which can be attributed to different protocol, sequence, and method of performing MRI in both studies.

Buchanan *et al.* [29] emphasized the value of the diagnostic efficacy of MRI in recurrent and complex FIA. The authors concluded that the preoperative assessment of FIA with MRI helped proper surgical planning which successfully reduced the rate of postoperative recurrence by as much as 75%. This was reproduced in our study as less than 5% of patients developed postoperative recurrence of anal fistula although the vast majority of anal fistulas were complex and around one-quarter were already recurrent after previous procedures.

Despite the relatively high rate of FI reported in our study, the degree of incontinence was minor either to flatus or to mucus. This high incontinence rate can be explained that most of the patients had a trans-sphincteric FIA which involves a significant portion of the external anal sphincter, thus affection of the anal sphincter integrity and function can be anticipated even with the use of a sphincter-saving procedure for all patients.

Although the present study was able to demonstrate the diagnostic utility of MRI fistulography in assessing FIA, some limitations to the study should be acknowledged. The retrospective nature of the study renders it a level IV

evidence which is the main limitation. Lack of some information about the patients' characteristics as body mass index, smoking, and associated diabetes mellitus is also another limitation to the study. Finally, to elucidate the actual prognostic value of MRI fistulography, a comparison has to be made between patients with complex FIA who were examined by MRI and those who did not receive MRI examination preoperatively.

## 5. Conclusion

MRI fistulography is an effective diagnostic modality for the preoperative assessment of anal fistulas. MRI had excellent accuracy and sensitivity in detection of the internal opening, primary tract, and secondary extensions of anal fistula with very good concordance with the intraoperative findings on EUA. The prognostic value of MRI fistulography in decreasing the recurrence and incontinence rates has to be verified in further prospective studies.

## References

- [1] Saino, P. "Fistula-in-ano in a defined population: incidence and epidemiological aspects." *Ann. Chir. Gynaecol.* 1984; 73: 219–224.
- [2] Buchanan G, Halligan S, Williams A, *et al.* Effect of MRI on clinical outcome of recurrent fistula-in-ano. *Lancet* 2002; 360: 1661–1662.
- [3] Chapple KS, Spencer JA, Windsor AC, Wilson D, Ward J, Ambrose NS. Prognostic value of magnetic resonance imaging in the management of fistula-in-ano. *Dis Colon Rectum* 2000; 43: 511–516.
- [4] D'Hoore A, Penninckx F. The pathology of complex fistula in ano. *Acta Chir Belg* 2000; 100: 111–114.
- [5] Maier AG, Funovics MA, Kreuzer SH, *et al.* Evaluation of perianal sepsis: comparison of anal endosonography and magnetic resonance imaging. *J Magn Reson Imaging* 2001; 14: 254–260.
- [6] Schwartz DA, Wiersema MJ, Dudiak KM, *et al.* A comparison of endoscopic ultrasound, magnetic resonance imaging, and exam under anesthesia for evaluation of Crohn's perianal fistulas. *Gastroenterology* 2001; 121: 1064–1072.
- [7] Morris J, Spencer JA, Ambrose NS. MR imaging classification of perianal fistulas and its implications for patient management. *Radiographics* 2000; 20 (3): 623–635.
- [8] Ziech M, Felt-Bersma R, Stoker J. Imaging of perianal fistulas. *Clin Gastroenterol Hepatol* 2009; 7 (10): 1037–1045.
- [9] Horsthuis K, Lavini C, Bipat S, Stokkers PC, Stoker J. Perianal Crohn disease: evaluation of dynamic contrast-enhanced MR imaging as an indicator of disease activity. *Radiology* 2009; 251 (2): 380–387.
- [10] Spencer JA, Ward J, Ambrose NS. Dynamic contrast enhanced MR imaging of perianal fistulae. *Clin Radiol* 1998; 53: 96–104.

- [11] deSouza NM, Kmiot WA, Puni R et al. High resolution magnetic resonance imaging of the anal sphincter using an internal coil. *Gut* 1995; 37: 284–287.
- [12] Kołodziejczak M, Santoro GA, Obcowska A, Lorenc Z, Mańczak M, Sudoł-Szopińska I. Three-dimensional endoanal ultrasound is accurate and reproducible in determining type and height of anal fistulae. *Colorectal Dis.* 2016; doi: 10.1111/codi.13580.
- [13] Siddiqui MR, Ashraffian H, Tozer P, Daulatzai N, Burling D, Hart A. A diagnostic accuracy meta-analysis of endoanal ultrasound and MRI for perianal fistula assessment. *Dis Colon Rectum.* 2012; 55 (5): 576-85. doi: 10.1097/DCR.0b013e318249d26c.
- [14] Jorge JM, Wexner SD. Etiology and management of fecal incontinence. *Dis Colon Rectum.* 1993; 36: 77–97.
- [15] Morris J, Spencer JA, Ambrose NS. MR Imaging Classification of Perianal Fistulas and Its Implications for Patient Management. *Radiographics.* 2000 May-Jun; 20 (3): 623-35; discussion 635-7.
- [16] Emile SH, Elfeki H, Thabet W, Sakr A, Magdy A, Abd El-Hamed T, Omar W, Khafagy W. Predictive Factors for Recurrence of High Trans-sphincteric Anal Fistula after Placement of Seton. *J Surg Res.* 2017. DOI: <http://dx.doi.org/10.1016/j.jss.2017.02.053> [Epub Ahead of Print].
- [17] Ratto C, Grillo E, Parello A, Costamagna G, Doglietto GB. Endoanal ultrasound-guided surgery for anal fistula. *Endoscopy.* 2005; 37 (8): 722–8. doi: 10.1055/s-2005-870155.
- [18] Lunniss PJ, Armstrong P, Barker PG, Reznick RH, Phillips RK. Magnetic resonance imaging of anal fistulae. *Lancet.* 1992; 340: 394–396. doi: 10.1016/0140-6736(92)91472-K.
- [19] Torkzad MR, Karlhom U. MRI for assessment of anal fistula. *Insights into Imaging.* 2010; 1 (2): 62-71. doi: 10.1007/s13244-010-0022-y.
- [20] West RL, Zimmerman DD, Dwarkasing S, Hussain SM, Hop WC, Schouten WR, Kuipers EJ, Felt-Bersma RJ. Prospective comparison of hydrogen peroxide-enhanced three-dimensional endoanal ultrasonography and endoanal magnetic resonance imaging of perianal fistulas. *Dis Colon Rectum.* 2003; 46 (10): 1407–1415. doi: 10.1007/s10350-004-6758-z.
- [21] Maier AG, Funovics MA, Kreuzer SH, Herbst F, Wunderlich M, Teleky BK, Mittlböck M, Schima W, Lechner GL. Evaluation of perianal sepsis: comparison of anal endosonography and magnetic resonance imaging. *J Magn Reson Imaging.* 2001; 14 (3): 254–260. doi: 10.1002/jmri.1181.
- [22] O'Malley RB, Al-Hawary MM, Kaza RK, et al. Rectal Imaging: Part 2, Perianal Fistula Evaluation on Pelvic MRI – What the Radiologist Needs to Know. *Am J Roentgenol.* 2012; 199 (1): 43–53.
- [23] Horsthuis K, Lavini C, Bipat S, Stokkers PC, Stoker J. Perianal Crohn disease: evaluation of dynamic contrast-enhanced MR imaging as an indicator of disease activity. *Radiology.* 2009; 251 (2): 380–387. doi: 10.1148/radiol.2512072128.
- [24] Spencer JA, Chapple K, Wilson D, Ward J, Windsor ACJ, Ambrose NS. Outcome after surgery for perianal fistula: predictive value of MR imaging. *AJR Am J Roentgenol* 1998; 171: 403-406.
- [25] Mahjoubi B, Kharazi HH, Mirzari R, et al. Diagnostic accuracy of body coil MRI in describing the characteristics of perianal fistulas. *Colorectal Dis.* 2005; 8 (2): 202–7.
- [26] Lo Re G, Tudisca C, Vernuccio F, Picone D, Cappello M, Agnello F, Galia M, Galfano MC, Biscaldi E, Salerno S, Pinto A, Midiri M, Lagalla R. MR imaging of perianal fistulas in Crohn's disease: sensitivity and specificity of STIR sequences. *Radiol Med.* 2016 Apr; 121 (4): 243-51. doi: 10.1007/s11547-015-0603-4.
- [27] Waniczek D, Adamczyk T, Arendt J, Kluczevska E. Direct MRI fistulography with hydrogen peroxide in patients with recurrent perianal fistulas: a new proposal of extended diagnostics. *Med Sci Monit.* 2015 Feb 10; 21: 439-45. doi: 10.12659/MSM.891232.
- [28] Beets-Tan RG, Beets GL, van der Hoop AG, et al. Preoperative MRI of anal fistulas: Does it really help the surgeon? *Radiology.* 2001; 218: 75–84.