

**Review Article**

# Transsphenoidal Endoscopic Approach in Treatment of Spontaneous Nasal CSF-leak

Sergei Karpishchenko<sup>1</sup>, Vladislav Cherebillo<sup>2</sup>, Olga Vereshchagina<sup>1</sup>, Nikita Puzakov<sup>2</sup>,  
Olga Stancheva<sup>1,\*</sup>

<sup>1</sup>Department of Otorhinolaryngology, Pavlov First Saint Petersburg State Medical University, St. Petersburg, Russia

<sup>2</sup>Department of Neurosurgery, Pavlov First Saint Petersburg State Medical University, St. Petersburg, Russia

**Email address:**

karpishchenkos@mail.ru (S. Karpishchenko), cherebillo@mail.ru (V. Cherebillo), wereschagina@yandex.ru (O. Vereshchagina),  
n.puzakov@gmail.com (N. Puzakov), olga.stancheva@yandex.ru (O. Stancheva)

\*Corresponding author

**To cite this article:**

Sergei Karpishchenko, Vladislav Cherebillo, Olga Vereshchagina, Nikita Puzakov, Olga Stancheva. Transsphenoidal Endoscopic Approach in Treatment of Spontaneous Nasal CSF-leak. *Journal of Surgery*. Vol. 7, No. 6, 2019, pp. 198-201. doi: 10.11648/j.js.20190706.19

**Received:** November 13, 2019; **Accepted:** December 11, 2019; **Published:** December 23, 2019

---

**Abstract:** Spontaneous nasal liquorrhea is a pathological condition associated with defects between the nasal cavity and the intracranial structures, which results in CSF leak from the nasal cavity. Diagnostic criteria include: anamnesis, examination of the nasal fluid, endoscopic examination of the nasal cavity, and CT - and MRI - cisternography. Conservative therapy is applicable to small fistulas. In the case of the inefficiency of this method, surgical method is then applied to the defect closure. *Purpose of the study:* To evaluate the effectiveness of endoscopic endonasal approach in the CSF leak treatment. *Materials and methods:* For the period from 2008 to 2018 at the Pavlov First Saint Petersburg State Medical University, at the clinic of neurosurgery of the Kirov Medical Institute and the Medical Research Center Almazov, 38 patients with spontaneous nasal liquorrhea were treated. All patients underwent plastic surgery of the CSF fistula by endoscopic endonasal approach. *Results:* In 4 cases, there was a large defect requiring secondary surgical intervention 1-2 weeks after the initial operation. *Conclusions:* The use of auto tissues (muscle or fat) is the method of choice for repeated surgical plastics of the cerebrospinal fluid fistula or in the case of a large size defect.

**Keywords:** Nasal Liquorrhea, Skull Base, Autograph

---

## 1. Introduction

Spontaneous nasal liquorrhea is a pathological condition resulting in leakage of cerebrospinal fluid from the nasal cavity for the patients without any trauma or some nasal surgery.

According to various articles, the frequency of this pathology ranges from 41.1% to 64.6% from all CSF-leakage [1], [2]. A skull base defect can be formed because of bone osteoporosis, inflammatory changes, a tumor process, and also can be congenital.

From all clinical symptoms the most often complains of the patients are rhinorrhea and headaches [3]. Sometimes as the first manifestations of CSF-leak can be intracranial complications, such as meningitis or encephalitis. [1].

The diagnostic algorithm includes few steps and begins

with the analysis of the patient's complains and medical history. After that the physician provides the analysis of intranasal fluid which is taken as cerebrospinal fluid. There should be performed the determination of glucose with the use of glucose tests strips and / or determination of the  $\beta$ -2 fraction of transferrin (tau protein) [4]. The nasal endoscopy and computed tomography of the paranasal sinuses cannot be informative in case of small defect. In such cases, when it is not possible to determine the source of liquorrhea by the previous research methods, they resort to CT cisternography [5] or MRI cisternography [6]. The first method of analysis is the most sensitive, it can detect the definitely localization of a bone defect in 87% of cases [6].

The typical localization of the cerebrospinal fluid fistula is: the ethmoid plate, the posterior and lateral walls of the

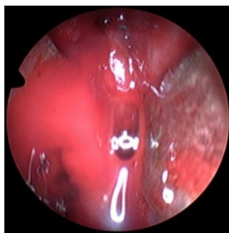
sphenoid sinus [7], especially the lateral wall and the cribriforme plate [8]. Less often a skull base defect is located in the posterior wall of the frontal sinus or in the pyramid of the temporal bone. In comparison with all paranasal sinuses, the sphenoid is one of the most deeply located and, as a result, has a location close to the skull base structures.

Many researchers noticed the connection between the spontaneous liquorrhea and hyperpneumatization of the sphenoid sinus, especially in the lateral part of it. This anatomical feature lead to bone resorption of the skull base, prolapse and rupture of the dura mater, especially in situations with suddenly increase of intracranial pressure [9]. Another reason of CSF-leak is related with syndrome of the “empty” turcica cella, when intrasellar arachnoidocele displaces the pituitary gland to the posterior wall of the sphenoid sinus. Such position contributes to the formation of a defect on the base of the turcica sella and the leakage of CSF through the formed fistula.

At the recent time, there are two treatment options for spontaneous nasal liquorrhea: conservative method (prescribing of dehydrating therapy, antibiotics and lumbar drainage) and surgical treatment. Surgical treatment includes closure of the cerebrospinal fluid fistula especially with the use of endonasal endoscopic approach [10], [11]. Depending on the size of the cerebrospinal fluid defect it is more preferable to use combined transpterigoidal, transsphenoidal, and transtmoidal approaches [12], [13]. The type of the flap which is used to close the defect depends on its size and location. As an example, plastic surgery of a small fistula (up to 5 mm) requires the use of only one type of topical haemostatic agent (Tachocomb®). If the defect is located on the cribriforme plate or ethmoid bone, then surgical closure should involve the application of several layers of transplantation material or the use of vascular flaps (vascular pedicle nasoseptal flap). According to various authors, the efficiency of cerebrospinal fluid fistula closure with the use of transnasal endoscopic techniques ranges from 70 to 97% [14-16].

## 2. Materials and Methods

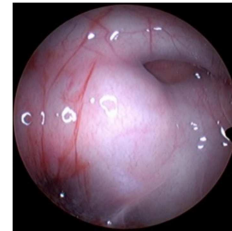
At the I.P. Pavlov Medical State University, at the Department of Neurosurgery, in association with the Department of Otorhinolaryngology, an analysis of patients with spontaneous nasal liquorrhea for the period from 2008 to 2018 was performed. All the patients underwent the surgical procedure for the skull base defect closure. Of the total number of patients (38 patients), there were 23 women and 15 men, the average age was 41.4 years (26 to 62 years). In 23 patients there was observed a combination of a bone defect with a fistula of the dura mater in the cribriform plate [Figure 1].



**Figure 1.** Approach to the skull base.

In 14 patients, the defect was localized in the lateral areas of the sphenoid sinus [Figure 2], and in one case in the region of the Blumenbach stingray.

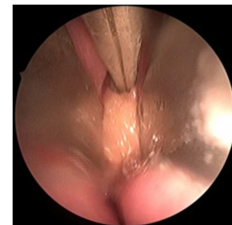
To diagnose nasal liquorrhea as well as to determine the location and size of the cerebrospinal fluid fistula, all patients, in addition to the standard examination, underwent CT-cisternography. In 12 cases out of 38, it was possible to identify the source of nasal liquorrhea during a standard endoscopic examination of the nasal cavity with the help of rigid endoscopes.



**Figure 2.** Liquorrhea in the sphenoid sinus.

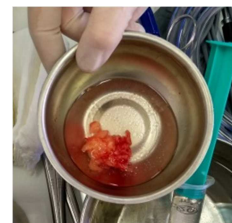All examined patients underwent plastic surgery of the cerebrospinal fluid fistula with endoscopic endonasal approach. When closing the cerebrospinal fluid fistula, which was located in the region of the sieve plate, up to 5 mm in size, in 19 cases there was used a combination of an adsorbing haemostatic substance (Tachocomb®) [Figure 3] and fibrin-thrombin surgical glue Tissucol [17].

Package of the operating area was carried out with the hemostatic absorbable material “Surgical Fibrillar” [18].



**Figure 3.** Packing of the skull base defect with a haemostatic substance.

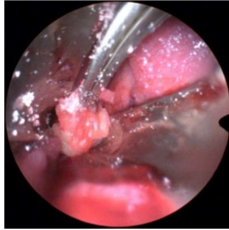
The primary plastic of the cerebrospinal fluid fistula was found in 4 cases to be insolvent due to relapse of nasal liquorrhea after 1-2 weeks. These patients required repeated surgical procedure for closing of the defect with the use of autografts (abdominal fat flap) [Figure 4] [19].



**Figure 4.** Fat autograft.

When the defect is localized in the sphenoid sinus it is easy to make a revision of this area using the endoscopes with the different angles. After that, fat autograft should be installed

under the mucous flap. This flap is fixed with hemostatic substance (Tachocomb®) and Evicel surgical glue [Figure 5].



**Figure 5.** Fat autograft placement.

Due to increased intracranial pressure in 12 cases lumbar drainage was performed for a period of 3 days after the operation with daily removal of 120-150 milliliters of cerebrospinal fluid. In addition to the above, antibacterial and dehydration therapy was prescribed to the patient.

In all cases, a soft packing of the nasal cavity was performed on the side of the surgical intervention with the haemostatic absorbable material Syrgicel Fibrillar for up to 3 days.

### 3. Results

The follow-up period was 2-6 months after surgery. Relapse of cerebrospinal fluid fistula was observed in 3 cases in the ethmoid cells area and in one case in the lateral part of the hyperpneumatic sphenoid sinus. Primary surgical repair of the defect with a single-layer method showed ineffectiveness due to relapses development of nasal liquorrhea 1-2 weeks after the surgery. While secondary surgery, a complex flap with a fat autograft was used. In the follow-up period the resumption of liquorrhea was not determined. In all cases the complications of spontaneous liquorrhea, such as meningitis, brain abscess, or pneumocephaly was not developed.

### 4. Discussion

Spontaneous nasal liquorrhea is the process of leakage of cerebrospinal fluid into the nasal cavity as a result of some anatomical features. The frequency of this condition occurred in the range of 4-39% among all cases of nasal liquorrhea [2]. This pathology is often found in women, with the big body mass index, in the 3-4 decades of life. In the diagnostic algorithm, indicated by increasing sensitivity and specificity of the method, one can distinguish: glucose test,  $\beta$ 2-transferrin test and endoscopy of the nasal cavity, neuroimaging (CT and MRI cysternography). The method of treatment depends on the severity of the condition and the number of recurrence of the disease. Because of the duration of this disease in the long term period, meningitis and other complications may develop. It is happened due to decrease in barrier function between the brain and nasal cavity which isn't sterile. Uncomplicated forms of spontaneous nasal liquorrhea have good response on the conservative treatment: bed rest, lumbar drainage, antihypertensive and antibacterial drugs prescribed to the patient. Surgical treatment consists of a combination of

methods, such as lumboperitoneal bypass surgery and an extracranial approach or an endoscopic approach to cerebrospinal fluid fistula. In modern neurosurgery, preference is given to the endoscopic approach, which provides wide visualization and accurate localization of the defect. Same results were shown by our department. As it can be seen, the success from closing the spontaneous nasal cerebrospinal fluid fistula with this approach gives more than 80% good clinical outcomes [20]. The most reliable flap to close the defect is a tissue autograft, in our case, a fat transplant that is placed in the area of the cerebrospinal fluid. The development of relapses of this technique cannot be ruled out (up to 15%) due to the size of the defect and the nature of intracranial hypertension.

### 5. Conclusion

According to our observations we came to the following conclusions:

- 1) the usage of autografts (fat or muscle) in surgical closure of the skull base defects significantly increases the reliability of closing the cerebrospinal fluid fistula;
- 2) it is necessary to use a collagen sponge and surgical glue in case of small defects of the skull base;
- 3) lumbar drainage is justified to reduce cerebrospinal fluid pressure and thus decreases intracranial pressure;
- 4) to reduce liquor production in postoperative management of patients dehydration therapy is prescribed as well as antibacterial therapy for the cases with the complex flap.

### Acknowledgements

The authors express their gratitude to the staff of the Neurosurgeon Department and the Otorhinolaryngology Department of First Pavlov State Medical University of Saint Petersburg for provided materials.

### References

- [1] Shintoku, R., Tosaka, M., Shimizu, T., and Yoshimoto, Y. (2018). Transcranial and epidural approach for spontaneous cerebrospinal fluid leakage due to meningoencephalocele of the lateral sphenoid sinus. *Asian journal of neurosurgery*. 13 (2): 462.
- [2] Subhanov, K. S., Abdulkarimov, V. Y., Cherebillo, V. Y., Svistov, D. V., and Konovalov, P. P. (2017). Surgical treatment of nasal liquorrhea. *Uralskiy meditsinskiy zhurnal*. 150 (6): 122-126.
- [3] Karpishchenko, S. A., Voloshina, A. V., Stancheva, O. A. and Yusupov, D. (2019). Acute isolated sphenoiditis: tactics and treatment. *Zhurnal Vrach*. Vol. 4: 259-261.
- [4] Shelesko, E. V., Kravchuk, A. D., Kapitanov, D. N., Chernikova, N. A., and Zinkevich, D. N. (2018). A modern approach to the diagnosis of nasal liquorrhea. *Zhurnal Voprosy Neurokhirurgii Imeni N. N. Burdenko*. 82 (3): 103-111.

- [5] Vlasova, M. M., and Piskunov, I. S. (2016). The possibilities of computed tomography in the diagnosis of spontaneous nasal liquorrhea. *Ros. otorhinolaryngologia*. 24 (2): 13-19.
- [6] Karpishchenko, S. A., Cherebillo, V. Y., Tamazyan, N. V., Puzakov, N. S., Stancheva, O. A. and Danilova, D. M. (2018). Features of endonasal transsphenoidal access in the surgical volume of the pituitary adenoma. *Ros. otorhinolaryngologia*. Vol. 3: 47-53.
- [7] Larin, R. A., and Pisarev, E. N. (2013). Spontaneous liquorrhea nasalis when skull base defects is located in sphenoidal sinus. *Sovremennyye tekhnologii v meditsine*. 5 (3): 122-123.
- [8] Martínez-Capoccioni, G., Serramito-García, R., Martín-Bailón, M., García-Allut, A., and Martín-Martín, C. (2017). Spontaneous cerebrospinal fluid leaks in the anterior skull base secondary to idiopathic intracranial hypertension. *European Archives of Oto-Rhino-Laryngology*. 274 (5): 2175-2181.
- [9] Lobo, B. C., Baumanis, M. M., and Nelson, R. F. (2017). Surgical repair of spontaneous cerebrospinal fluid (CSF) leaks: A systematic review. *Laryngoscope investigative otolaryngology*. 2 (5): 215-224.
- [10] Gofman, V. R., Andronenkov, V. A., and Voronov, A. V. (2012). The substantiation of the approach for endoscopic surgery of nasal liquorrhea. *Vestnik otorinolaringologii*. Vol. 4: 16-17.
- [11] Kljajić, V., Vuleković, P., Vlaški, L., Savović, S., Dragičević, D., and Papić, V. (2017). Endoscopic repair of cerebrospinal fluid rhinorrhea. *Brazilian Journal of Otorhinolaryngology*. 83 (4): 388-393.
- [12] Piskunov, V. S. and Nikitin, N. A. (2016). Possibilities of endoscopic surgery in the treatment of nasal liquorrhea. *Innova*. Vol. 4: 5.
- [13] Schwartz, T. H., Fraser, J. F., Brown, S., Tabae, A., Kacker, A., and Anand, V. K. (2008). Endoscopic cranial base surgery: classification of operative approaches. *Neurosurgery*. 62 (5): 991-1005.
- [14] Chaaban, M. R., Illing, E., Riley, K. O., and Woodworth, B. A. (2014). Spontaneous cerebrospinal fluid leak repair: a five-year prospective evaluation. *The Laryngoscope*. 124 (1): 70-75.
- [15] Gaidukov, S. S., and Naumenko, A. N. (2014). Criteria for choosing a method for plasty of defects in the base of the skull in patients with nasal liquorrhea. *Ros. otorhinolaryngologia*. Vol. 1: 33-36.
- [16] Karpishchenko, S. A., Stancheva, O. A. and Suvorkina, A. D. (2017). Features of the diagnosis and treatment of isolated fungal lesions of the sphenoid sinus. *Folia Otorhinolaryngologiae et Pathologiae Respiratoriae*. 23 (3): 50-57.
- [17] Sharipov, O. I., Kutin, M. A., Bayuklin, A. V., Imaev, A. A., Abdilatipov, A. A., Kurnosov, A. B., Fomichev, D. V., Mikhaylov, N. I., and Kalinin, P. L. (2018). The use of platelet gel for repair of a cerebrospinal fluid fistula of the skull base (a case report and literature review). *Zhurnal Voprosy Neurokhirurgii Imeni N. N. Burdenko*. 82 (1): 86-92.
- [18] Polezhaev, A. V., Cherebillo, V. Y., Svistov, D. V., Tsoy, D. V., and Voycehovskiy, D. V. (2018). Transsphenoid surgery of nasal liquorrhea as a complication of drug treatment with prolactin. *Vestnik khirurgii imeni I. I. Grekova*. 177 (3): 14-18.
- [19] Pashaev, B. Y., Bochkarev, D. V., Danilov, V. I., Krasnozhen, V. N., and Vagapova, G. R. (2015). The prevention and treatment of nasal liquorrhea in transnasal surgery of the base of the skull. *Vestnik otorinolaringologii*. 80 (4): 34-37.
- [20] Gaivoronsky, A. I., Kondakov, E. N., Svistov, D. V., and Gulyaev, D. A. (2015). Surgical access in neurosurgery (a guide for doctors). By decision of the scientific council VMedA. Edited by B. V. Gaidar. SPb.