



Post-Splenectomy Portal Venous Thrombosis in Cirrhotic Patients: An Observational Clinical Trial

Hamdy Sedky Abd Allah*, Mohamad Hamdy Abo-Ryia, Sherif Abd-Al Fattah Saber

General Surgery Department, Faculty of Medicine, Tanta University, Tanta, Egypt

Email address:

Hamdy.abdallah@med.tanta.edu.eg (H. S. A. Allah)

*Corresponding author

To cite this article:

Hamdy Sedky Abd Allah, Mohamad Hamdy Abo-Ryia, Sherif Abd-Al Fattah Saber. Post-Splenectomy Portal Venous Thrombosis in Cirrhotic Patients: an Observational Clinical Trial. *Journal of Surgery*. Vol. 5, No. 6, 2017, pp. 105-110. doi: 10.11648/j.js.20170506.14

Received: September 22, 2017; **Accepted:** October 4, 2017; **Published:** November 12, 2017

Abstract: *Background:* Post-splenectomy portal venous thrombosis (PS-PVT) carries multiple threats to patients' lives. Different variables were identified as risk factors for PS-PVT in cirrhotic patients. The aim of this study was to prospectively assess the incidence, risk factors, clinical presentation and treatment outcomes of PS-PVT in cirrhotic patients. *Patients and methods:* Sixty cirrhotic patients of Child class A submitted to open splenectomy were observed, both clinically and by Duplex ultrasound (US) examination, for the development of PS-PVT. *Results:* Overall, 17 patients (28.3%) developed PS-PVT at a median interval of 4.5 days (21 hours-7 days) post-splenectomy. Univariate analysis showed that lower preoperative platelet count ($P<0.0460$) and white blood cell (WBC) count ($P<0.0001$) and wider splenic vein diameter (SVD) ($P<0.0001$) correlated with PS-PVT. Multivariate analysis identified lower preoperative WBC count [odds ratio (OR): 0.651, 95% confidence interval (CI): 0.245-0.893, $P<0.005$] and wider SVD (OR: 2.383, 95% CI: 1.558-3.646, $P<0.001$) as independent risk factors of PS-PVT. While 16 out of the 17 patients (94%) who had these 2 risk factors developed PS-PVT, only 1 out of the 43 patients (2.3%) who didn't have the same risk factors developed thrombosis. All 17 patients had complete resolution of their thrombosis on anticoagulation therapy within 3-6 months without complications or mortality. *Conclusion:* PVT is a common complication of splenectomy in cirrhotic patients. Patients with low WBC count and wide SVD are highly susceptible to develop this complication mandating close observation from the 1st PO day and immediate anticoagulation after diagnosis.

Keywords: Splenectomy, Portal Vein Thrombosis, Cirrhosis, Risk Factors

1. Introduction

Egypt has the highest prevalence of hepatitis C virus (HCV) infection in the world [1, 2] reaching 22% in those aged 55-59 years in 2015 [3]. Liver cirrhosis develops in 48% of patients having co-infection with schistosomiasis [4]. In a community-based study in Nile Delta, 3% of tested subjects were cirrhotic and 67% of cirrhotic patients had portal hypertension [5].

Cirrhotic patients with portal hypertension frequently require splenectomy for various indications, including hypersplenism, thrombocytopenia developing before or during HCV treatment, thrombocytopenia in patients with hepatocellular carcinoma (HCC) and as a part of Hassab operation [6-9].

With an incidence of 16-52.6% in cirrhotic patients [10-

14], post-splenectomy portal venous thrombosis (PS-PVT) carries multiple threats to patients' lives including upper gastrointestinal bleeding, ischemic bowel necrosis, liver cell failure and refractory ascites [15, 16].

Since symptoms, such as abdominal pain and fever are non-specific and PS-PVT can easily develop without any symptoms, identification of high-risk patients is essential to allow starting anticoagulation immediately once the diagnosis is made [17, 18]. In one study, all patients treated within 10 days of splenectomy had complete resolution of the clot, in comparison to no patient whose treatment was initiated more than 10 days after splenectomy [19].

Different variables were identified as risk factors for PS-PVT in cirrhotic patients including a wider preoperative portal vein (PV) diameter [10, 13] or splenic vein diameter (SVD) [12, 14, 20, 21], preoperative low platelet [14] or white blood cell (WBC) counts [12], prolonged prothrombin

time [10], decreased antithrombin-III activity [20], postoperative thrombocytosis [10] and age >50 years [13]. The aim of this study was to prospectively assess the complication of PS-PVT in cirrhotic patients regarding its incidence, risk factors, clinical presentation and treatment.

2. Patients and Methods

2.1. Study Design

This observational clinical trial was conducted at the Gastrointestinal and Laparoscopic Surgery Unit, General Surgery Department, Tanta University, Tanta, Egypt during the period from March 2008 to March 2016. Cirrhotic patients of Child class A submitted to open splenectomy for symptomatic splenomegaly, 2ry hypersplenism or thrombocytopenia (Platelet count $<50 \times 10^3/\text{CC}$) were included in the study while cirrhotic patients of Child class B or C, patients with preoperative PVT and patients scheduled for splenectomy for other indications were excluded. An informed written consent was obtained from every patient and the study protocol was approved by the "Research Ethics Committee" of the Faculty of Medicine, Tanta University.

Preoperatively, the age, sex, hepatitis virus status, hemoglobin (Hb) concentration, platelet count, WBC count and international normalized ratio (INR) were collected. Preoperative Duplex Doppler ultrasound (US) for exclusion of PVT and measuring the SV diameter was performed. If not performed before, upper endoscopy was performed for control of esophago-gastric varices if indicated. No prophylactic anticoagulants were used. Splenectomy was performed through a left subcostal incision. Operative time and intraoperative blood product transfusion were recorded. Duplex Doppler US was performed at postoperative (PO) days 1,3,7 and 30. When PS-PVT was detected, its time, distribution and extent were recorded and therapeutic dose of heparin was started followed by oral anticoagulant. WBC and Platelet counts were measured at PO days 3, 7 and 30. PS-PVT was defined as either complete or partial thrombosis of the PV trunk, the PV branches or the superior mesenteric vein (SMV). Clinical signs and symptoms suggestive of PS-PVT were looked for and recorded. After discharge, Duplex Doppler US was repeated every month for a maximum of 6 months or till complete recanalization of the thrombosed vein.

2.2. Statistical Analysis

The primary end-point was the development of PS-PVT and secondary end-points included complications of PVT, complications of treatment and mortality. Data were tabulated and analyzed using SPSS statistics software package version 20. Continuous data were expressed as range, median and mean and were compared using the two-tailed, non-paired Student's *t*-test. Categorical data were expressed as frequencies and were compared using Fisher's exact test. Only variables that correlated positively with PS-PVT on univariate analysis were considered for multivariate analysis using the logistic regression model. *P* value <0.05 was considered statistically significant.

3. Results

The study population included 60 patients who were divided into 2 groups; group (A) included patients who developed PS-PVT and group (B) included patients who did not.

3.1. Pre-Operative Data [Table 1]

In group (A), there were 10 males (59%) and 7 females (41%) with a median age of 44 years (range 21-67, mean 40.9 years). The indications of surgery included symptomatic splenomegaly, 2ry hypersplenism and thrombocytopenia before or during HCV treatment in 4 (23.5%), 9 (53%) and 4 (23.5%) patients respectively. All patients had thrombocytopenia and the median preoperative platelet count was $45 \times 10^3/\text{CC}$ (range 22-145, mean $60.2 \times 10^3/\text{CC}$), the median preoperative WBC count was $1.81 \times 10^3/\text{CC}$ (range 1.4-3.3, mean $1.9 \times 10^3/\text{CC}$) and the median preoperative SVD was 14.3 mm (range 6-16, mean 13.5 mm).

In group (B), there was 25 males (58.1%) and 18 females (41.9%) with a median age of 41.2 years (range 23-60, mean 40.6 years). The indications of surgery included symptomatic splenomegaly, 2ry hypersplenism and thrombocytopenia in the course of HCV treatment in 8 (18.6%), 25 (58.1%) and 10 (23.3%) patients respectively. Thirty five patients (81.4%) had thrombocytopenia and the median preoperative platelet count was $82.5 \times 10^3/\text{CC}$ (range 25-240, mean $88.48 \times 10^3/\text{CC}$), the median preoperative WBC count was $6.4 \times 10^3/\text{CC}$ (range 3.5-9.3, mean $6 \times 10^3/\text{CC}$) while the median preoperative SVD was 8.5 mm (range 5-14, mean 6.5 mm).

Table 1. Pre-Operative Patients' Data.

Variable	Group A (No=17)		Group B (No=43)		P
	No	%	No	%	
Sex					
Male	10	59	25	58.1	1.0000
Female	7	41	18	41.9	1.0000
Median age (years)		40.8		41.2	0.986
HCV status					
Active infection	9	53	28	65	0.8142
Treated	8	47	14	32.5	0.5896
Median INR		1.4		1.3	0.3467
Median Hb concentration (gm/dl)		9.1		9.5	0.8425

Variable	Group A (No=17)		Group B (No=43)		P
	No	%	No	%	
Median platelet count ($\times 10^3/\text{CC}$)	45		82.5		0.0460
Median WBC count ($\times 10^3/\text{CC}$)	1.81		6.4		0.0001
Median SVD (mm)	14.3		8.5		0.0001
Indications of surgery					
Symptomatic splenomegaly	4	23.5	8	18.6	0.7366
2ry hypersplenism	9	53	25	58.1	1.0000
Thrombocytopenia	4	23.5	10	23.3	1.0000

HCV: Hepatitis C virus, Hb: Hemoglobin, WBC: white blood cell, INR: international normalized ratio, SVD: splenic vein diameter.

3.2. Operative Data [Table 2]

In group (A), the median number of units of packed red blood cells (RBC), blood platelets and fresh frozen plasma (FFP) per patient was 1, 3 and 1.5 units respectively. The median operative time was 84 minutes (range 95-120, mean

89 minutes). In group (B), the median number of units of packed red blood cells, blood platelets and FFP per patient was 1.3, 3 and 2 units respectively. The median operative time was 77 minutes (range 80-130, mean 78 minutes).

Table 2. Operative Data.

Variable	Group A (No=17)		Group B (No=43)		P
Blood products transfusion (median No. of units/patient)					
Packed RBC	1		1.3		0.4997
Blood platelets	3		3		0.3570
FFP	1.5		2		1.000
Median operative time (minutes)	84		77		0.3347

RBC: red blood cells, FFP: fresh frozen plasma.

3.3. Post-Operative Data [Table 3]

Overall, 17 patients (17/60; 28.3%) developed PS-PVT at a median interval of 4.5 days post-splenectomy. PS-PVT was diagnosed 21 hours after surgery in 1 patient (1/17; 5.9%), at the 3rd PO day in 9 patients (9/17; 52.9%) and at the 7th PO day in 7 patients (7/17; 41.2%).

The preoperative, operative and PO data of patients in both groups, including age, sex, HCV status, preoperative Hb concentration, WBC count, platelet count, INR, SVD, indications of surgery, operative time, intra-operative RBC, FFP and platelet transfusion, PO WBC and platelet count, were compared. On Univariate analysis, 3 variables correlated with PS-PVT including lower preoperative platelet count ($p < 0.0460$), lower preoperative WBC count ($P < 0.0001$) and wider SVD ($P < 0.0001$). Multivariate analysis

identified lower preoperative WBC count [odds ratio (OR): 0.651, 95% confidence interval (CI): 0.245-0.893, $P < 0.005$] and wider preoperative SVD (OR: 2.383, 95% CI: 1.558-3.646., $P < 0.001$) as independent risk factors of PS-PVT. In this study, 17 patients had low WBC count and wide SVD and 16 of them (16/17; 94%) developed PS-PVT. On the other hand, only 1 out of the 43 patients (1/43; 2.3%) who didn't have these 2 variables developed PS-PVT ($P < 0.0001$). Figure 1

The SV was totally thrombosed in all patients, the PV was totally thrombosed in 13 patients (13/17; 76.5%) and partially thrombosed in 4 patients (4/17; 23.5%) while the SMV was partially thrombosed in 5 patients (5/17; 29.4%) and without thrombosis in the remaining 12 patients (13/17; 70.6%).

Table 3. Post-Operative Data.

Variable	Group A (No=17)		Group B (No=43)		P
	No	%	No	%	
Median PO WBC count ($\times 10^3/\text{CC}$)	14.29		12.65		0.0012
Median PO platelet count ($\times 10^3/\text{CC}$)	620		690		0.5000
Timing of PS-PVT					
PO day 1	1	5.9	0	0	
PO day 3	9	52.9	1	5.9	
PO day 7	6	35.3	0	0	
Symptoms frequency of PS-PVT					
Overall		12 (70.6%)			
Abdominal pain/discomfort		9 (53%)			
Anorexia		6 (35.3%)			
Abdominal distension		5 (29.4%)			

PS-PVT: post-splenectomy portal venous thrombosis, WBC: white blood cell, PO: postoperative.

While 5 out of the 17 patients (5/17; 29.4%) who developed PS-PVT were entirely asymptomatic, 12 patients

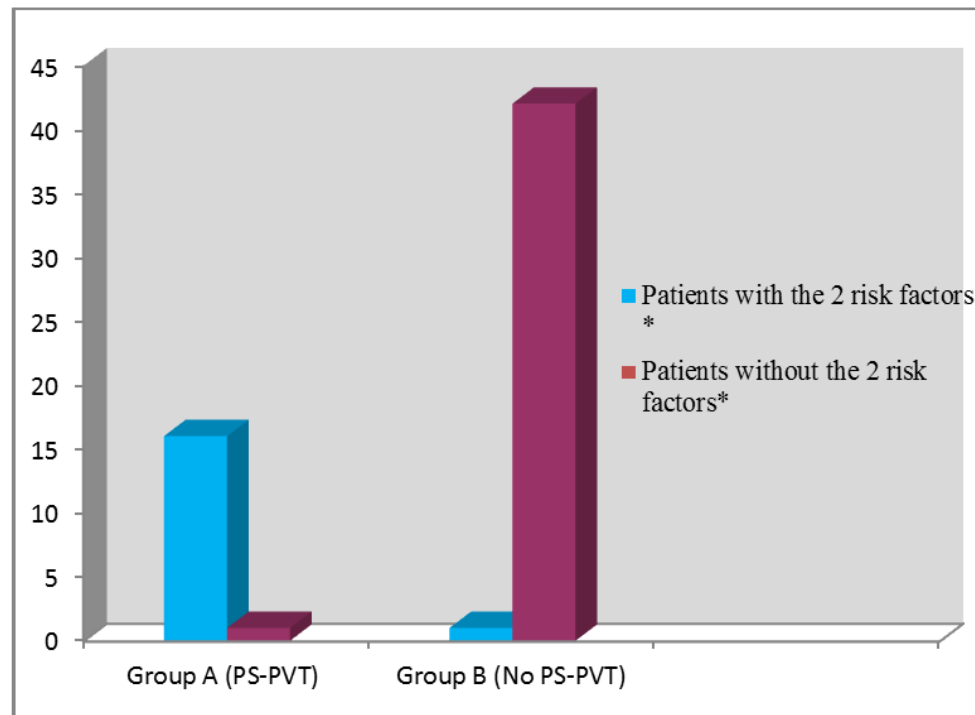
(12/17; 70.6%) developed symptoms correlated with the onset of PS-PVT including vague central abdominal

pain/discomfort in 9 patients (9/17; 53%), anorexia in 6 patients (6/17; 35.3%) and abdominal distension in 5 patients (5/17; 29.4%).

The WBC count increased in all patients in both groups reaching a maximum count of $14.29 \times 10^3/\text{CC}$ in group (A) (range $10-22 \times 10^3/\text{CC}$) peaking at the 6th PO day and $12.65 \times 10^3/\text{CC}$ in group (B) (range $11-15 \times 10^3/\text{CC}$) peaking at the 3rd PO day. The difference between the 2 groups was statistically significant ($P < 0.0012$). The platelet count increased in all patients reaching its peak at the 6th PO day; in group (A), the maximum platelet count was $620 \times 10^3/\text{cc}$

(range $120-900 \times 10^3/\text{CC}$) while in group (B), it was $690 \times 10^3/\text{CC}$ (range $120-760 \times 10^3/\text{CC}$). The difference between the 2 groups was statistically insignificant ($P < 0.5000$).

All patients with PS-PVT had complete resolution of the thrombus with recanalization of the PV and SMV on anticoagulation therapy within 3-6 months PO. None of these patients suffered upper GI bleeding, intestinal ischaemia, refractory ascites, liver cell failure or haemorrhagic complications secondary to anticoagulants. There was no mortality.



* Low preoperative white blood cell count and wide splenic vein diameter. PS-PVT: post-splenectomy portal venous thrombosis

Figure 1. Incidence of PS-PVT in Patients with and Without Low Preoperative WBC Count and Wide SVD.

4. Discussion

Portal vein thrombosis (PVT) is a frequent complication of splenectomy with a reported incidence of up to 50% in cirrhotic patients [14, 21]. Several risk factors have been suggested in different studies [10-14, 21].

In this study, we observed a cohort of cirrhotic patients submitted to open splenectomy, both clinically and by Duplex US, looking for the development of this complication. We relied on Duplex Doppler US for the diagnosis of PS-PVT. Color Duplex US imaging has a specificity of 99% and a sensitivity of 93%, while contrast-enhanced computed tomography (CT) is also highly specific (99%) but slightly less sensitive (90%) [22]. Advantages of CT over US include the possibility of detecting bowel ischemia and septic foci and higher sensitivity in the detection of partial venous thrombosis and thrombosis in the SV and SMV. The drawbacks of CT include exposure to ionizing radiation, the risk of allergic reactions and

nephrotoxicity [23].

The results of our study show that low WBC count ($<4 \times 10^3/\text{CC}$) and dilated splenic vein (diameter >13 mm) are independent risk factors for the development of PS-PVT in cirrhotic patients and patients who had these 2 variables showed a very high incidence of PS-PVT (94%) in comparison to a very low incidence of 2.3% in those patients without these 2 variables. Our results agree with those of some studies [12, 14, 20, 21] while other studies did not identify these 2 variables as risk factors for PS-PVT [10, 13].

After splenectomy of large spleen, PVT has been suggested to be due to the DSV acting as a low flow cul-de-sac in which stagnation of blood flow leads to thrombosis which then spreads into the PV [24]. Some authors recommend ligation of the splenic vein as close as possible to its junction with the inferior mesenteric vein (IMV) so that the stagnant segment of the SV is removed while blood keeps flowing from the IMV into the remaining segment of the SV [25].

The WBC count in our study increased in all patients PO

and the increase was significantly higher in group (A); a difference that represents a result rather than a cause of PVT. Although platelets are famous for their role in thrombus formation, there is significant evidence supporting an integral role for WBC in thrombosis and implying that leucocytosis may have a prothrombotic effect. Neutrophil-derived enzymes inhibit anticoagulants, such as tissue factor inhibitor, antithrombin III and Protein C [26-28] while activating factor XII and increasing expression of tissue factor [26, 27]. Oxidants released by neutrophils can inhibit degradation of von Willebrand factor producing a prothrombotic state [29]. Impaired degradation of neutrophil extracellular traps has been associated with acute thrombotic microangiopathies [30]. It was also found that neutrophils and monocytes are major components of thrombi formed at sites of flow restriction and that the arrival of leucocytes, in large quantities, preceded the formation of a thrombus, suggesting their early role in thrombosis. When leucocytes were depleted in mouse models, thrombosis either did not occur or the thrombi were significantly smaller [31].

About 70% of patients who developed PS-PVT in our study had symptoms including anorexia, abdominal pain and distension. Because many patients remain asymptomatic, the true incidence of PS-PVT may be underestimated [32] and suspicion of PVT should be entertained in any patient who develops vague and generalized abdominal pain, fever or leukocytosis within the first 30 days after splenectomy; manifestations that are quite nonspecific, vague and insidious in onset and therefore unhelpful in establishing the diagnosis [33].

Although the median interval between splenectomy and PVT in the current study was 4.5 days, an important observation is that PVT was diagnosed <24 hours after splenectomy in 1 patient (1/17; 5.9%). This observation underlines the importance of early screening in high risk patients. The median time from splenectomy to symptomatic PVT was 6, 10.7, 11.6 and 12 days PO in other study [19, 32, 34].

All patient with PS-PVT in our study received anticoagulation therapy immediately after the diagnosis was established and all of them had complete resolution of the thrombus in PV and SMV. It was reported that recanalization may occur in >90% of patients with acute PVT who are anticoagulated [35]. Rhee *et al* [36] demonstrated higher survival rates in patients with PVT who were anticoagulated compared with patients who were observed. In the van't Riet *et al* [19] series, all patients treated within 10 days of splenectomy had resolution of the clot versus no patient in whom treatment was initiated more than 10 days.

In our study, the preoperative platelet count was higher in group (A) than in group (B) patients and the difference between the 2 groups reached statistical significance on univariate analysis. On multivariate analysis, however, the difference failed to reach a statistical significance (OR: 0.958, 95% CI: 0.125-1.652, $P < 0.095$). Platelet count increased in all patients PO, but, the difference between the 2

groups did not reach a statistical significance on univariate analysis. The association between post-splenectomy thrombocytosis and PS-PVT is unclear. Not all patients with post-splenectomy thrombocytosis develop PVT, and this complication has been described in patients with normal or even low platelet counts [37]. Therefore, postoperative thrombocytosis, even if markedly elevated, cannot be considered the only cause of PVT [38].

The small sample size is one of the limitations of this study. Also, some variables which were identified as risk factors for PS-PVT as splenic weight and anti-thrombin III were not assessed in our study.

5. Conclusion

PS-PVT is a common complication in cirrhotic patients occurring in 28.3% of patients in the current study. Low preoperative WBC count and wide SVD were identified as independent risk factors of PS-PVT. Close observation, both clinically and by Duplex US, starting from the 1st PO day and immediate anticoagulation after diagnosis yield excellent outcomes.

Conflict of Interest Statement

All the authors do not have any possible conflicts of interest.

References

- [1] Shepard CW, Finelli L, Alter MJ (2005) Global epidemiology of hepatitis C virus infection. *Lancet Infect Dis* 5:558-67.
- [2] Sievert W, Altraif I, Razavi HA, *et al* (2011) A systematic review of hepatitis C virus epidemiology in Asia, Australia and Egypt. *Liver Int* 31:61-80.
- [3] El-Zanaty and Associates (2015) Egypt health issues survey 2015. Cairo, Egypt and Rockville, Maryland, USA: Ministry of Health and Population and ICF International 25-49.
- [4] Struthers A (2007) From schistosomiasis to hepatitis C: the spread of HCV in Egypt. *Med J Ther Africa* 1(3):213-21.
- [5] Darwish MA, Faris R, Darwish N, *et al* (2001) Hepatitis C and cirrhotic liver disease in the Nile delta of Egypt: A community-based study *Am J Trop. Med Hyg* 64:147-53.
- [6] Kercher KW, Carbonell AM, Heniford BT, Matthews BD, Cunningham DM, Reindollar RW (2004) Laparoscopic splenectomy reverses thrombocytopenia in patients with hepatitis C cirrhosis and portal hypertension. *J Gastrointest Surg* 8:120-6.
- [7] Hirooka M, Ishida K, Kisaka Y, *et al* (2008) Efficacy of splenectomy for hypersplenic patients with advanced hepatocellular carcinoma. *Hepatol Res* 38:1172-7.
- [8] Morihara D, Kobayashi M, Ikeda K (2009) Effectiveness of combination therapy of splenectomy and long-term interferon in patients with hepatitis C virus-related cirrhosis and thrombocytopenia. *Hepatol Res* 39:439-47.

- [9] Hassab MA, Younis MT, El-Kilany MS (1986) Gastroesophageal decongestion and splenectomy in the treatment of esophageal varices secondary to bilharzial cirrhosis: anatomical and experimental studies. *Surg* 63:731-37.
- [10] Li MX, Zhang XF, Liu ZW, Lv Y (2013) Risk factors and clinical characteristics of portal vein thrombosis after splenectomy in patients with liver cirrhosis. *Hepatobiliary Pancreat Dis Int* 12:512-519.
- [11] Yoshida M, Watanabe Y, Horiuchi A, Yamamoto Y, Sugishita H, Kawachi K (2009) Portal and splenic venous thrombosis after splenectomy in patients with hypersplenism. *Hepatogastroenterol* 56(90):538-41.
- [12] Kawanaka H, Akahoshi T, Tomikawa M et al (2010) Risk factors for portal venous thrombosis after splenectomy in patients with cirrhosis and portal hypertension. *British J Surg* 97:910-916.
- [13] Jiang G, Bai D, Chen P, Qian J, Jin S, Wang X (2016) Risk Factors for portal vein system thrombosis after laparoscopic splenectomy in cirrhotic patients with hypersplenism. *J laparoendosc & adv surg techn* 26(6):419-423.
- [14] Wu S, Wu Z, Zhang X, Wang R, Bai J (2015) The incidence and risk factors of portal vein system thrombosis after splenectomy and pericardial devascularization. *Turk J Gastroenterol* 26:423-428.
- [15] Stamou KM, Toutouzas KG, Kekis PB (2006) Prospective study of the incidence and risk factors of postsplenectomy thrombosis of the portal, mesenteric, and splenic veins. *Arch Surg* 141:663-669.
- [16] Pietrabissa A, Moretto C, Antonelli G, Morelli L, Marciano E, Mosc F (2004) Thrombosis in the portal venous system after elective laparoscopic splenectomy. *Surg Endosc* 18:1140-1143.
- [17] Winslow ER, Klingensmith ME, Brunt LM (2005) Problem of portal venous thrombosis after splenectomy. *Ann Surg* 242:745.
- [18] Miniati DN, Padidar AM, Kee ST, Krummel TM (2005) Mallory B. Portal vein thrombosis after laparoscopic splenectomy: an ongoing clinical challenge. *JSLS* 9:335-8.
- [19] Van't Riet M, Burger JWA, van Muiswinkel JM, Kazemier G, Schipperus MR, Bonjer HJ (2000) Diagnosis and treatment of portal vein thrombosis following splenectomy. *Br J Surg* 87:1229-33.
- [20] Kawanaka H, Akahoshi T, Itoh S, et al (2014) Decreased antithrombin III (ATIII) activity and large splenic vein diameter (SVD) Optimizing Risk Stratification in Portal Vein Thrombosis after Splenectomy and its Primary Prophylaxis with Antithrombin III Concentrates and Danaparoid Sodium in Liver Cirrhosis with Portal Hypertension. *J Am Coll Surg* 219:865-74.
- [21] Danno K, Ikeda M, Sekimoto M, et al (2009) Diameter of splenic vein is a risk factor for portal or splenic vein thrombosis after laparoscopic splenectomy. *Surgery* 145:457-64.
- [22] Bach AM, Hann LE, Brown KT, et al (1996) Portal vein evaluation with US: comparison to angiography combined with CT arterial portography. *Radiology* 201:149-54.
- [23] Margini C, Berzigotti A (2017) Portal vein thrombosis: The role of imaging in the clinical setting. *Digestive and Liver Disease* 49:113-20.
- [24] Eguchi A, Hashizume M, Kitano S, Tanoue K, Wada H, Sugimachi K (1991) High rate of portal vein thrombosis after splenectomy in patients with esophageal varices and idiopathic portal hypertension. *Arch Surg* 126:752-55.
- [25] Boissel P, Bresler L, Trackeon G, Poussot D, Gosdidiier (1991) Mesenteric and portal vein thrombosis following splenectomy in hematologic diseases. A report of 3 cases. *Chirurgie* 117:591-95.
- [26] Borisoff JJ, ten Cate H (2011) From neutrophil extracellular traps release to thrombosis: an overshooting host-defense mechanism? *J Thromb Haemost* 9:1791-94.
- [27] Massberg S, Grahl L, von Bruehl ML, et al (2010) Reciprocal coupling of coagulation and innate immunity via neutrophil serine proteases. *Nat Med* 16:887-96.
- [28] Levi M, van der Poll T, Buller HR (2004) Bidirectional relation between inflammation and coagulation. *Circulation* 109:2698-704.
- [29] Ruggeri ZM (2007) The role of von Willebrand factor in thrombus formation. *Thromb Res* 120 (Suppl 1):S5-S9.
- [30] Jimenez-Alcazar M, Napirei M, Panda R, et al (2015) Impaired DNase1-mediated degradation of neutrophil extracellular traps is associated with acute thrombotic microangiopathies. *J Thromb Haemost* 732-42.
- [31] von Bruhl ML, Stark K, Steinhart A, et al (2012) Monocytes, neutrophils, and platelets cooperate to initiate and propagate venous thrombosis in mice in vivo. *J Exp Med* 209:819-35.
- [32] Romano F, Caprotti R, Conti M, et al (2006) Thrombosis of the splenoportal axis after splenectomy. *Langenbecks Arch Surg* 391:483-88.
- [33] Benoist S (2000) Les complications a moyen et long term de la splenectomie. *Ann Chir* 125:317-24.
- [34] Ikeda M, Sekimoto M, Takiguchi S, et al (2007) Total splenic vein thrombosis after laparoscopic splenectomy: a possible candidate for treatment. *Am J Surg* 193:21-5.
- [35] Condat B, Pessione F, Denninger MH, et al (2000) Recent portal or portal vein thrombosis: increased recognition and frequent recanalization on anticoagulant therapy. *Hepatology* 32:466-70.
- [36] Rhee RY, Gloviczki P, Mendonca CT, et al (1994) Portal vein thrombosis: still a lethal disease in the 1990s. *J Vasc Surg* 20:688-97.
- [37] Winslow ER, Brunt LM, Drebin JA, Soper NJ, Klingensmith ME (2002) Portal vein thrombosis after splenectomy. *Am J Surg* 184:631-6.
- [38] Rossi P, Passariello R, Simonetti G (1976) Portal Thrombosis: High Incidence Following Splenectomy for Portal Hypertension. *Gastrointest Radiol* 1:225-7.