



Autologous Reconstruction Following Nipple Sparing Mastectomy Achieves Equivalent Aesthetic Outcome as Natural Breasts

Peter Deptula*, Youna Choi, Nhung Tran, Danielle Rochlin, Dung Nguyen

Division of Plastic and Reconstructive Surgery, Stanford University, Stanford, USA

Email address:

pdeptula@stanford.edu (P. Deptula)

*Corresponding author

To cite this article:

Peter Deptula, Youna Choi, Nhung Tran, Danielle Rochlin, Dung Nguyen. Autologous Reconstruction Following Nipple Sparing Mastectomy Achieves Equivalent Aesthetic Outcome as Natural Breasts. *Journal of Surgery*. Vol. 9, No. 4, 2021, pp. 170-175.

doi: 10.11648/j.js.20210904.15

Received: June 2, 2021; **Accepted:** June 15, 2021; **Published:** June 22, 2021

Abstract: We determined the aesthetic outcomes of autologous breast reconstruction in comparison to cosmetically altered or natural breasts. We also examined the effect of perceptions on aesthetic outcomes of breast reconstruction. Images of 10 patients (autologous breast reconstruction following bilateral nipple sparing mastectomy (NSM) (n=5), bilateral breast reduction (n=1), bilateral mastopexy (n=1), bilateral augmentation (n=1), unoperated natural breasts (n=2)), were compiled into a blind three-part survey. Part one asked participants to determine whether the presented breasts are reconstructed after mastectomy and measure aesthetic outcomes (1=poor and 4=excellent). Part two ranks breasts from most desirable to least desirable. Part three presents side-by-side unlabeled pre and postoperative images of patients who have undergone autologous breast reconstruction and asks to select the more aesthetically pleasing breasts. Two thousand images were quantified from 100 surveys (83.3% response rate). Age range of participants was 18-80. Response was not statistically different based on demographics. The rate of correctly identifying breasts as reconstruction after NSM was 62.8% and as natural was 64%. Mean aesthetic scores between the reconstructed and natural breasts were equivalent. Breasts perceived as reconstruction scored significantly lower in five aesthetic factors. The top 3 most desired breasts were augmentation, reconstruction after NSM, and unoperated natural breasts. In paired pre- and postoperative photo comparison, all responses favored postoperative breasts. Aesthetic outcomes after autologous breast reconstruction can be equivalent to natural breasts. Breasts perceived as reconstruction are ranked poorer in aesthetic factors compared to those perceived as natural breasts.

Keywords: Autologous Breast Reconstruction, Patient Expectations, Perceptions, Breast Reconstruction

1. Introduction

Breast reconstruction following mastectomy has increased not only in number but also in technical advancements. [1-3] Studies emphasizing patient-reported outcomes have demonstrated how mastectomy impacts patient quality of life, body image, depression, sexual well-being and function. [4-7] The proven safety and improved aesthetics of nipple sparing mastectomy paired with breast reconstruction advances have resulted in improved psychological and aesthetic outcomes following mastectomy. [1]

Through advances in breast reconstruction technique, improvements in cosmetic outcome have followed. [3] These

improved cosmetic outcomes following breast reconstruction have been shown to associate with improvements in quality of life, body image, social and emotional functioning and depression. [5] Not surprisingly, greater weight has been placed on the cosmetic outcomes of breast reconstruction. [5] Autologous breast reconstruction in particular has been shown to result in improved long-term satisfaction and improved quality of life. [2, 8-10] This notion has proven particularly true of abdominal-based autologous reconstruction. [9, 10]

There is a paucity of literature regarding the general public's perceptions of breast reconstruction. The idea that breast reconstruction results in inferior cosmetic outcomes

have previously been described. [3] This notion is in direct contrast to the expectations of improved aesthetic results and improved body image seen in cosmetic breast augmentation patients. [11] In fact, there is also evidence that patients have very little accuracy regarding expectations surrounding breast reconstruction. [12] Given the advances of breast reconstruction, our authors hypothesize that autologous breast reconstruction can achieve aesthetic outcomes comparable to cosmetic breast surgery. We therefore designed a survey-based study including clinical images to a diverse group of clinical and non-clinical participants in an effort to understand differences in perceptions of autologous breast reconstruction and cosmetic breast surgery. We determined the aesthetic outcomes of autologous breast reconstruction in comparison to outcomes of cosmetically altered or natural breasts. We also examined the effect of perceptions on aesthetic outcomes in breast reconstruction in an effort to guide preoperative expectations.

2. Methods

A blinded three-part survey was developed. The survey included unlabeled images of a total of 14 de-identified patients (autologous breast reconstruction following nipple sparing mastectomy (NSM) (n=7), bilateral breast reduction (n=1), bilateral mastopexy (n=1), bilateral augmentation (n=1), unoperated natural breasts (n=4)). All patients were presented in the same anterior-posterior view. Part one of the survey asks whether participants believe 10 presented breasts are reconstructed after mastectomy, and measure aesthetic outcomes by scoring: natural appearance, size, contour, symmetry, position of breasts, position of nipples, and scars (1=poor, 4=excellent). A sample of survey image and questions is shown in Figure 1. Part two ranks breasts from 1

(most desirable) to 10 (least desirable). Part three presents unlabeled pre and postoperative images of 5 patients who have undergone autologous breast reconstruction and asks participants to select the more aesthetically pleasing breasts. Face validity of the survey was confirmed by authors prior to administration.

Post-operative photos were taken at 12-month or after and represent the final post-operative result; no further revision procedures were planned. Cases of autologous breast reconstruction were performed by the senior author. Cases of cosmetic breast surgery were performed by outside plastic surgeons. All mastectomies were performed for breast cancer. Patients did not receive radiation therapy or chemotherapy.

The survey was administered to a broad group of participants over 18 years of age. Participants were identified in the hospital setting as well as in the public space. Participant demographic data was collected in regard to age, gender, ethnicity, occupation and medical specialty. Survey results and demographic data were recorded in a de-identified fashion. Statistical analysis was performed using χ^2 and two-tailed t-tests. P-values less than 0.05 were determined to be statistically significant.

3. Results

A total of 120 volunteers were identified and willing to complete the survey. 100 surveys were completed (response rate of 83.3%). Age range of participants was 18-80 (average 36.35). Participants included non-healthcare professionals (64.0%) and healthcare professionals (36.0%). Healthcare professionals included those in and outside the field of plastic surgery (20.0% vs 80.0%). The demographic data of survey participants is summarized in table 1.

Table 1. Demographics Survey Participants.

Age	Average 36.35 years (±14.7 SD), Range (18-80 years)					
Gender	Male (37.0%)			Female (63.0%)		
Healthcare	36.0% (Medical Student 5%, Resident 10%, APP 6.0%, Staff 10.0%, Attending 4.0%)					
	Plastic Surgery (20.0%)			Non-plastic Surgery (80.0%)		
Non-Healthcare	64.0%					
Ethnicity	Asian (53.0%)	Black (4.0%)	Hispanic (12.0%)	White (1.0%)	Pacific Islander (29.0%)	Other (1.0%)

The overall rate of correctly identifying reconstructed breasts was 62.8% and natural (unoperated or cosmetically altered) was 64% (p=0.74). Healthcare workers were able to successfully identify the type of breast surgery at a rate of 67.2%, while non-healthcare workers were successful 61.2% of the time (p=0.06). There were no significant differences in correct identification in regard to gender (male 65.4%, female 62.2%) or age (p=0.63). No significant differences between the type of healthcare worker were seen (medical student 66.0%, resident 76%, APP 63.3%, office staff 64.0% and attending surgeons 56.7%). However, participants who identified as part of the plastic surgery specialty demonstrated an increased ability to correctly identify the type of procedure compared those who identified as part of another healthcare specialty (69.0% vs 62.0%, p=0.0069).

The overall average aesthetic score for reconstructed breasts was 3.2, while natural breasts scored 3.3 (p=0.65). Average aesthetic sub-scores for reconstructed breasts included: natural appearance 2.8, size 3.0, contour 2.8, symmetry 2.7, position 2.9, nipple position 2.7 and scars 2.49. Average aesthetic sub-scores for cosmetically altered natural breasts included natural appearance 2.9, size 3.0, contour 2.7, symmetry 2.7, position 2.6, nipple position 2.7, and scars 3.1. Statistically significant differences between sub-scores of reconstructed and cosmetically altered natural breasts were noted in breast position (2.88 vs 2.62, p<0.001) and scars (2.49 vs 3.05, p<0.001).

When performing similar analyses for the perceived type of breast surgery, significant differences were noted. Breasts perceived as reconstruction received an average aesthetic

score of 2.6, while breasts perceived as natural received an average aesthetic score of 2.9 ($p<0.05$). Significant differences in aesthetic sub-scores were noted in terms of natural appearance (2.6 vs 3.1), contour (2.7 vs 2.8), Symmetry (2.6, 2.8), nipple position (2.6 vs 2.8) and scars (2.3 vs 3.2).

Breasts that had the highest scores in terms of desirability included cosmetic augmentation (2.54), reconstruction after nipple sparing mastectomy (4.38) and unoperated natural breasts (4.68). In reviewing paired pre- and post-operative photos, all participants identified the post-operative breast as favorable (100.0%, $p<0.001$). (Figure 5)

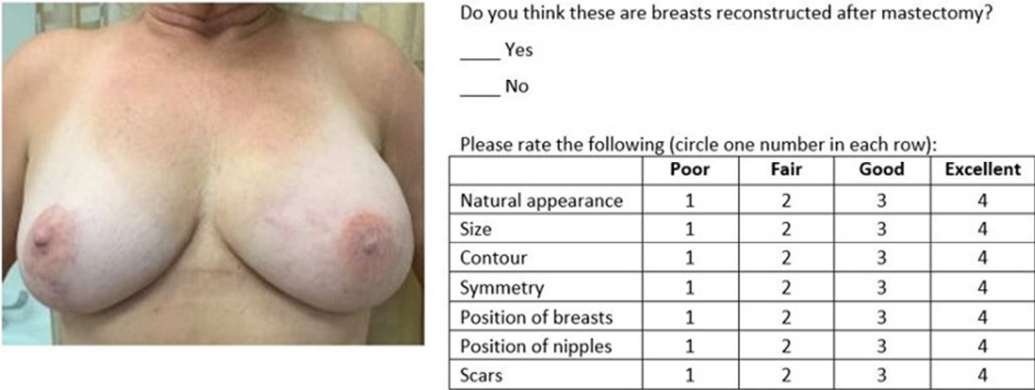


Figure 1. Sample layout of survey part 1.

Survey asks participants whether they believe the featured breasts were reconstructed after mastectomy. Subsequently participants are asked to assign aesthetic scores in seven subcategories to each presented set of breasts.

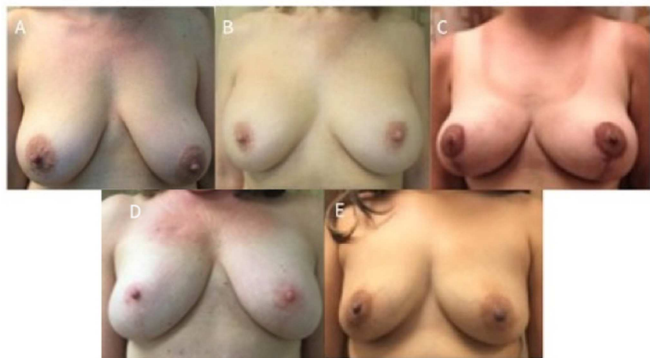


Figure 2. Survey Images for cosmetic breast surgery and natural breasts.

The above images A-E represent cosmetically altered or natural breasts. Patients A and E represent natural breasts. Patient B underwent cosmetic augmentation. Patient C underwent reduction mammoplasty. Patient D underwent bilateral mastopexies.

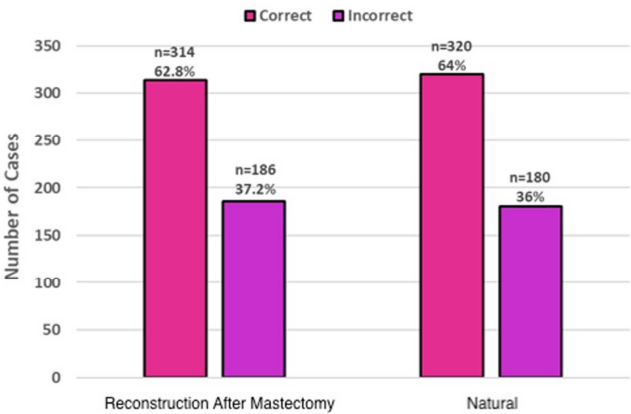


Figure 4. Ability to predict type of breast surgery.

Survey participants' ability to accurately identify breasts that are reconstructed after mastectomy and natural breasts.

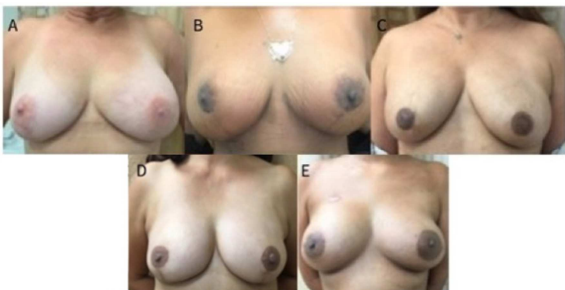

Figure 3. Survey images for reconstruction with autologous breast reconstruction.

The above images A-E represent patients who underwent breast reconstruction with free flaps following nipple-sparing mastectomy. Patients A, B and E had bilateral MS TRAM flaps. Patient C had bilateral DIEP flaps. Patient D underwent bilateral transverse upper gracilis flaps.

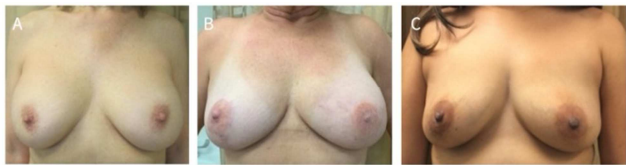

Figure 5. Top three ideal breasts.

The top three ideal breasts as determined by average aesthetic scores by survey participants. Patient A underwent cosmetic augmentation (average score 2.54). Patient B underwent bilateral nipple sparing mastectomies and reconstruction with autologous reconstruction with abdominal based free flap (average score 4.38). Patient C represents a patient with natural breasts that have not undergone surgical intervention (average score 4.68).

4. Discussion

This body of work demonstrates a perception amongst the general public that aesthetic outcomes of breast reconstruction are inferior to cosmetic breast surgery. Our authors argue that this study disproves the perception as autologous breast reconstruction has the potential to achieve aesthetic outcomes that are equivalent to cosmetic breast surgery. These conclusions are supported by our findings that the general population was not able to differentiate reconstructed breasts from cosmetically altered breasts at significantly different rates. In addition, breasts perceived as reconstructed received significantly inferior aesthetic scores. Interestingly, the top three ranked breasts included autologous reconstructed breasts along with augmentation and natural breasts, further supporting this notion. Lastly, our finding that all post-operative photos of patients who underwent autologous breast reconstruction were seen as superior in aesthetic outcome further support the idea that reconstruction can result in a pleasing aesthetic outcome.

This study follows Rochlin et al who previously reported on similar misperceptions in breast reconstruction. [3] The authors demonstrated in a similar survey-based study that modern implant-based breast reconstruction was able to achieve outcomes comparable to cosmetic breast augmentation surgery. [3] In the prior study, the authors found that participant age was the only demographic factor influencing the accuracy of identifying surgery type and perceived aesthetic outcome. [3] Our current study did not find any differences in regard to age, sex, or ethnicity with the exception of affiliation with plastic surgery. In this sense, the current study also departs from previous reports of the concept of the ideal breast having age, sex and ethnic biases. [3, 13, 14] However, our study revealed individuals within the field of plastic surgery were found to have a better ability to differentiate between autologous breast reconstruction and natural or cosmetically altered breasts. This is a logical finding, training in the field of plastic surgery entails proficiency in breast reconstruction and increased exposure to this population of patients. However, the previously study by Rochlin et al did not demonstrate this finding. [3]

Aesthetic scores between reconstructed and natural or cosmetically altered breasts demonstrated significant differences when accounting for participant perceptions. Breasts perceived as reconstructed were assigned lower aesthetic scores compared to breasts that were perceived as natural or cosmetically altered. In fact, all aesthetic sub-scores were lower when participants perceived breasts as reconstructed. These findings support the notion that breast reconstruction is associated with poorer cosmetic outcomes in the public opinion. [3]

Sub-score differences in breast position and scars were the only significant findings amongst other aesthetic factors of natural appearance, symmetry, contour, size, and nipple position. Breast reconstruction often involves larger scars compared to cosmetic breast surgery, which aligns with this finding. Breast position in reconstructed breasts received

higher scores, which corresponds to the reconstructive surgeon's ability to set the breast position on the chest wall. The same sub-score differences were observed in the previous study by Rochlin et al. [3] Similarly, Huis in 't Velt et al found delayed-immediate breast reconstruction to have improved overall aesthetic outcomes, particularly breast position along with contour and size. [15] They also assessed outcomes of scar formation between delayed and delayed-immediate reconstruction, no significant differences were found. [15]

The general public's views have previously been studied in regards to perceptions in breast reconstruction. [3, 16] Azadgoli et al used internet-based crowdsourcing to investigate the importance of the nipple in breast reconstruction. The authors found the majority of the general public viewed breasts without a nipple as incomplete, further advocating for nipple reconstruction. They also demonstrated that survey participants were willing to undergo additional procedures to achieve aesthetic nipple reconstruction. The authors' findings indicated that the general population's views on breast reconstruction aligned with that of the patients'. We similarly suggest that superior aesthetic outcomes following autologous reconstruction as determined by the general public may help patients decide whether or not to undergo breast reconstruction.

Cordova et al demonstrated in their systematic review that patient reported outcomes were more favorable with breast reconstruction following mastectomy. [17] The authors found that higher education and socioeconomic status influenced patients' decision to undergo breast reconstruction. [1, 17] In addition, higher education levels were associated with increased satisfaction and better pre-operative decision making. [17] Our authors agree that the preoperative discussion and decision making process is important and must consist a broad approach to patient education which also addresses common misperceptions regarding breast reconstruction. These decisions have demonstrated to impact quality of life. Specifically, autologous breast reconstruction has previously been shown to result in improved long-term satisfaction and quality of life. [2, 8-10] Fanakidou et al determined women who underwent reconstruction experienced improved mental health, stress and anxiety levels. [18] Women without reconstruction were found to have higher levels of loneliness. [18] Our authors suggest that reconciling misperceptions in autologous breast reconstruction can support decisions which ultimately may lead to improvements in quality of life.

Other studies have also discussed the superior cosmetic outcomes of autologous breast reconstruction using free abdominal tissues. Yueh et al demonstrated that autologous breast reconstruction resulted in greater general and aesthetic patient satisfaction. [9] This was particularly true for patients undergoing abdominal-based breast reconstruction. [9] Our authors agree with these conclusions as our study demonstrated the superior aesthetic outcome of autologous breast reconstruction with abdominal free tissue transfer. O'Halloran et al suggested the strong emphasis on

aesthetic outcomes may be a driving factor for younger patients to undergo breast reconstruction following mastectomy. [1] In light of our present study, there is increasing evidence to suggest that patients are looking for improved aesthetic outcomes in their preoperative decision making algorithm.

Our findings raise an important discussion regarding preoperative counseling for patients undergoing breast reconstruction. Previous studies have demonstrated that patients lack accurate preoperative expectations. [12] In particular, there are some patients who have unrealistic expectations regarding their reconstruction and may be left with postoperative thoughts feeling as if they “look like a freak” as described by Snell *et al.* [12] Our authors do not suggest that all autologous breast reconstruction outcomes will have superior cosmetic outcomes. However, we have demonstrated the potential of breast reconstruction from a cosmetic standpoint and support the previous studies that advocate for realistic preoperative expectations.

Limitations of our present study include its voluntary nature. While a diverse volunteer group was identified, the subjects do not necessarily reflect the demographic makeup of the general public. The single-surgeon nature of the study may also impart error as results may vary according to surgeon. This study also does not discuss patient satisfaction, which is arguably the most important factor in reconstructive outcome and the central focus of validated patient reported outcome instruments. We also acknowledge the great variety in breast reconstruction outcomes and emphasize that the current study highlights the potential of breast reconstruction using autologous tissues. Finally, this study relies solely on visual outcomes when ideal breast reconstruction also involves components of softness, sensation, and limited donor site morbidity. [10, 19]

5. Conclusion

Aesthetic outcomes after autologous breast reconstruction can be equivalent to natural breasts. Post-operative breasts were ranked poorer in aesthetic factors when they were perceived to be reconstructed by the general public. Plastic surgery providers are better able to discern the differences between reconstructed and cosmetically altered natural breasts. We suggest that discrediting misperceptions regarding cosmetic outcomes of autologous breast reconstruction may better assist patients with their preoperative decision-making process. By highlighting the aesthetic potential of autologous breast reconstruction, the superior patient satisfaction and quality of life may also expand broader group of patients.

References

- [1] O'Halloran N, Lowery A, Kalinina O, *et al.* Trends in breast reconstruction practices in a specialized breast tertiary referral centre. *BJS Open* 2017; 1 (5): 148-157.
- [2] Panchal H, Matros E. Current Trends in Postmastectomy Breast Reconstruction. *Plast Reconstr Surg* 2017; 140: 7S-13S.
- [3] Rochlin DH, Davis CR, Nguyen DH. Breast Augmentation and Breast Reconstruction Demonstrate Equivalent Aesthetic Outcomes. *Plast Reconstr Surg Glob Open* 2016; 4 (7) e811.
- [4] Dikmans REG, van de Grift TC, Bouman MB, *et al.* Sexuality, a topic that surgeons should discuss with women before risk-reducing mastectomy and breast reconstruction. *Breast* 2019; 43: 120-122.
- [5] Batenburg MCT, Gregorowitsch ML, Maarse W, *et al.* Patient-reported cosmetic satisfaction and the long-term association with quality of life in irradiated breast cancer patients. *Breast Cancer Res Treat* 2019 Oct 24 [ePub]. <https://rdcu.be/b0NBt>.
- [6] Pusic AL, Klassen AF, Scott AM, *et al.* Development of a New Patient-Reported Outcome Measure for Breast Surgery: The BREAST-Q. *Plast Reconstr Surg* 2009; 124 (2): 345-353.
- [7] Pusic AL, Chen CM, Cano S, *et al.* Measuring Quality of Life in Cosmetic and Reconstructive Breast Surgery: A Systematic Review of Patient-Reported Outcomes Instruments. *Plast Reconstr Surg* 2007; 120 (4): 823-837.
- [8] Villa MT. Patient-Reported Aesthetic Satisfaction with Breast Reconstruction during the Long-Term Survivorship Period. *Plast Reconstr Surg* 2009; 124 (1): 1-8.
- [9] Yueh JH, Slavin SA, Adesiyun T, *et al.* Patient Satisfaction in Postmastectomy Breast Reconstruction: A Comparative Evaluation of DIEP, TRAM, Latissimus Flap, and Implant Techniques. *Plast Reconstr Surg* 2010; 125 (6): 1585-1595.
- [10] Tevlin R, Wan DC, Momeni A. Should free deep inferior epigastric artery perforator flaps be considered a quality indicator in breast reconstruction? *J Plast Aesthet Surg* 2019; 72 (12): 1923-1929.
- [11] Crerand CE, Infield AL, Sarwer DB. Psychological Considerations in Cosmetic Breast Augmentation. *Plast Surg Nurs* 2009; 29 (1): 49-57.
- [12] Snell L, McCarthy C, Klassen A, *et al.* Clarifying the Expectations of Patients Undergoing Implant Breast Reconstruction: A Qualitative Study. *Plast Reconstr Surg* 2010; 126 (6): 1825-1830.
- [13] Rapisio E, Belgrano V, Santi P, *et al.* Which is the Ideal Breast Size? Some Social Clues for Plastic Surgeons. *Ann Plast Surg* 2016; 76 (3): 340-345.
- [14] Broer PN, Juran S, Walker ME, *et al.* Aesthetic Breast Shape Preferences Among Plastic Surgeons. *Ann Plast Surg* 2015; 74 (6): 639-644.
- [15] Huis t Veld EA, Long C, Sue GR, *et al.* Analysis of Aesthetic Outcomes and Patient Satisfaction After Delayed-Immediate Autologous Breast Reconstruction. *Ann Plast Surg* 2018; 80 (5S Suppl 5): S303-S307.
- [16] Azadgoli B, Gould DJ, Vartanian E, *et al.* The Public's Perception on Breast and Nipple Reconstruction: A Crowdsourcing-Based Assessment. *Aesthet Surg J* 2019; 39 (9): NP370-NP376.
- [17] Cordova LZ, Hunter-Smith DJ, Rozen WM. Patient reported outcome measures (PROMs) following mastectomy with breast reconstruction or without reconstruction: a systematic review. *Gland Surg* 2019; 8 (4): 441-451-451.

- [18] Fanakidou I, Zyga S, Alikari V, et al. Mental health, loneliness, and illness perception outcomes in quality of life among young breast cancer patients after mastectomy: the role of breast reconstruction. *Qual Life Res* 2018; 27 (2): 539-543.
- [19] Zhou A, Ducic I, Momeni A. Sensory restoration of breast reconstruction – The search for the ideal approach continues. *J Surg Onc* 2018; 118 (5): 780-792.