

Postoperative Enterocutaneous Fistula: A Severe and Desperate Complication in a Disadvantaged Surgical Setting

Soumaoro Labile Togba^{1,*}, Fofana Houssein¹, Fofana Naby¹, Kondano Saa Yawo¹, Thea Kokolye², Toure Aboubacar¹, Diallo Aissatou Taran¹

¹Department of General Surgery, Ignace Deen National Hospital, Conakry, Guinea

²Department of General Surgery, Regional Hospital of N'Zerekore, N'Zerekore, Guinea

Email address:

soumaoro66@gmail.com (S. L. Togba)

*Corresponding author

To cite this article:

Soumaoro Labile Togba, Fofana Houssein, Fofana Naby, Kondano Saa Yawo, Thea Kokolye, Toure Aboubacar, Diallo Aissatou Taran. Postoperative Enterocutaneous Fistula: A Severe and Desperate Complication in a Disadvantaged Surgical Setting. *Journal of Surgery*. Vol. 10, No. 1, 2022, pp. 4-7. doi: 10.11648/j.js.20221001.12

Received: November 15, 2021; **Accepted:** December 1, 2021; **Published:** January 12, 2022

Abstract: Purpose: Digestive or gastrointestinal fistula is one of the most feared postoperative complication along with dehiscence and infection. The aim of this study was to determine the etiological, clinical and therapeutic aspects of enterocutaneous fistulas in a disadvantaged surgical setting. Methods: This was a retrospective study covering a period of three years (January 2018 to December 2020) including records of patients managed for postoperative enterocutaneous fistula in the general surgery department of the Ignace DEEN national hospital in Conakry (Guinea). Results: During the three years of study, we compiled 69 records of patients with postoperative enterocutaneous fistulas, representing 14.68% of all postoperative abdominal complications registered in the department (n=468). The mean age of the patients was 29.61±17.32 years. In this series, 53 patients (76.81%) were initially operated in private health facilities and then referred to our department after the occurrence of the fistula. The most frequent indications for initial surgery were typhoid ileal perforation (37.68%) followed by appendicitis (26.09%) and sigmoid colon volvulus (15.94%). Spontaneous closure of the fistula was obtained in 41 patients (59.42%) with a mean time of 23 days. We noted 18 deaths (26.09%). Conclusion: Postoperative enterocutaneous fistula is a severe complication whose management in our environment is difficult and desperate for both patient and surgeon.

Keywords: Enterocutaneous Fistula, Management, Disadvantaged Environment

1. Introduction

Digestive or gastrointestinal fistula is one of the most feared postoperative complication along with dehiscence and infection [1]. It is a dreaded complication quite common in abdominal, digestive, gynecological or urological surgery [1-6]. They generally affect fragile subjects who have undergone multiple operations, in poor general condition, often elderly with comorbidities, which makes their management difficult. The overall incidence of postoperative enterocutaneous fistulas is hard to determine because in the literature, most publications concern the study of clinical observations [2-6]. Although the morbidity and mortality associated with enterocutaneous fistulas have decreased over

the past 50 years with the progress in resuscitation and treatment modalities, the overall mortality is still surprisingly high ranging from 6.5 to 39% [7-10] in the literature. This study aimed to determine the etiological, clinical and therapeutic aspects of enterocutaneous fistulas in our context of limited resources surgical environment.

2. Patients and Methods

This was a retrospective study covering a period of three years (January 2018 to December 2020) including medical records of patients treated for postoperative enterocutaneous fistula in the general surgery department of the Ignace DEEN National Hospital of Conakry (Guinea). This is a university

referral hospital, which receives patients in first-line consultation or referred from peripheral health facilities. Medical records with a complete medical observation, a well annotated treatment plan and data on follow-up for at least three months after discharge were included. The parameters studied were the socio-demographic characteristics of the patients (age, sex, profession), the factors of comorbidity, the indication and the procedure performed during the initial surgery, the causes and characteristics of the fistula (circumstance of discovery, time of onset, output), the therapeutic methods and results.

3. Results

During the three years of study, we compiled 69 cases of postoperative enterocutaneous fistulas, representing 14.68% of all postoperative abdominal complications observed in the department (n=468). The mean age of the patients was 29.61 ± 17.32 years with extremes of 10 and 82 years. The age group of 20 to 40 years old was the most concerned (68.12%). Females, unemployed, were predominant (71.01%). In the series, 65 patients (94.20%) underwent emergency surgery and 53 (76.81%) had initial surgery in private health structures then referred to our department after the

occurrence of the fistula. In this group, 19 patients unsuccessfully underwent a re-intervention to treat the fistula before being referred. Table 1 shows information on the initial surgery. The fistula was discovered by the observation of an abnormal flow of digestive fluid through the abdominal drain orifice (n=34), the incision (n=24) or both (n=11). The mean time to onset of fistula was 6.13 days (extremes: 2 and 17 days). The fistula was ileal in 27 cases (39.13%), colonic in 42 cases (60.87%). In the majority of cases (73.91%), the fistula output was low. Clinically, the patients showed signs of dehydration (73.91%), malnutrition (55.07%; Figure 1), anemia (79.71%) and fever (57.97%). Locally, skin degradation around the efferent orifice (suppuration, loss of skin substance) was noted in 82.61% and evisceration in 27.54% of cases (Figures 2 and 3). Overall, there was no evidence of intraperitoneal sepsis. Natural bowel transit (stool and gas) was preserved in more than half of the patients (56.52%). Laboratory tests showed neutrophilic hyperleukocytosis, a mean hemoglobin level of 8.13 g/dl, positive HIV serology in 11 patients (15.94%) and 5 cases (7.25%) of diabetes. Bacteriological, biochemical and radiological contrast examinations (enema with water-soluble solutions, CT scan with digestive opacification) were not performed.

Table 1. Information on the initial surgery.

Initial pathology	Initial surgical procedure	N	%
Ileal perforation of typhoid origin	Excision/suture of the perforation	26	37.68
Appendicitis	Appendectomy	18	26.08
Volvulus of the sigmoid colon	Left hemicolectomy/one-stage anastomosis	11	15.94
Small bowel obstruction	Small bowel segmental resection/anastomosis	6	8.70
Colon/rectum tumor	Segmental resection/anastomosis	4	5.80
Uterine fibroma	Myomectomy/repair of inadvertent bowel injury	4	5.80
Total		69	100

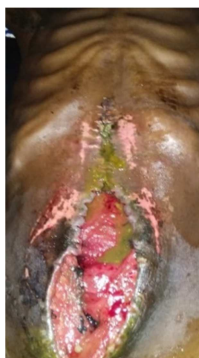
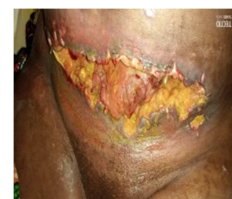
Figure 1. A 26 year-old with an iterative fistula following surgery for sigmoid volvulus. After three unsuccessful reinterventions to repair, the fistula persists with an alteration of the skin around and severe malnutrition.

In all cases, the medical treatment consisted of: rehydration, parenteral administration of antibiotics, vitamins, amino acids, blood transfusion and local care with absorbent dressings and a fistula collection device (Figure 3). Spontaneous closure of the fistula was obtained in 41 patients (59.42%) with a mean time of 23 days. Re-intervention was performed for persistence of the fistula (n=21) and

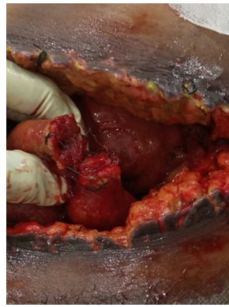occurrence of intra-abdominal sepsis (n=7). The mean time to re-intervention was 19.4 days with extremes of 3 and 37 days. Cases of diabetes were managed concomitantly while HIV patients were referred to the specialized service after closure of the fistula.



A

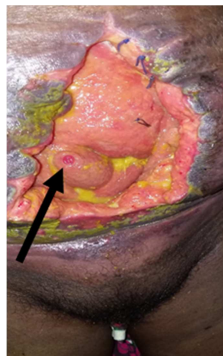


B

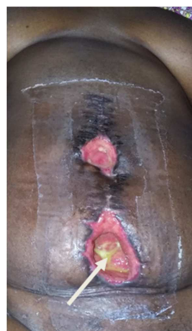

C

Figure 2. A 29 year-old woman presenting an evisceration with fistula (2A) following a surgery for uterine fibromyoma. The figure 2B shows a homemade collecting bag. At re-intervention, a total leakage of an anastomosis performed at the initial operation to treat an accidental opening of the ileum is observed (2C).



A



B

Figure 3. A 34 year-old woman with an evisceration and ileal fistula (3A, black arrow) following surgery for ileal perforation of typhoid origin. After re-intervention for the appearance of an intra-abdominal sepsis (segmental ileal resection/anastomosis), the fistula persisted with a low flow (3B, white arrow).

The evolution was favorable in 51 patients (73.91%). We recorded 18 deaths (26.09%) of which 13 among the re-intervention group.

The mean duration of hospitalization was 32.78 days with extremes of 13 and 67 days.

4. Discussion

Enterocutaneous fistula whether spontaneous or postoperative, is a desperate event in the abdominal surgical setting. The overall incidence of postoperative fistulas is

difficult to elucidate because in the literature, most studies are based on series of clinical observations [2-6]. During a period of three years, we recorded 69 cases of postoperative enterocutaneous fistulas representing 14.68% of all postoperative abdominal complications in the department. In UK, Hollington P *et al* [11] reported 277 consecutive enterocutaneous fistula over an 11 years period in a major tertiary referral center; while in India, Mohanty SK *et al* [6] noted 30 cases in two years. This difference of cases numbers could be explained by the method of recruitment but also by the level of the health structure concerned. In our environment, these fistulas occurred in young subjects initially operated on in emergency for benign pathologies such as ileal perforation of typhoid origin, appendicitis, intestinal obstruction [2-4]. In these contexts, ligatures, sutures and anastomoses performed in a highly septic environment are more likely to result in fistulas by loosening or simply leakage. It may also be an inadvertent opening of the coecum or ileum, a slipped stump ligature and a too low appendix stump amputation [4, 12]. The increasing number of non-employed medical graduates in our country in the last ten years has contributed largely to the setting of clandestine medical clinics and the illegal practice of surgery by non-specialized agents. This reality explains the high number of patients initially operated in private health structures (76.81%) and fistulas related to appendectomies (26.09%) noted in this study.

In general, these fistulas appear as early as the end of the first week after the initial surgery [3, 4, 12]. In our study, we noted extremes of 2 and 17 days. This could be related to the existence or not of an abdominal drain orifice or a dehiscence of the surgical wound.

The diagnosis of fistula is essentially clinical and easy by the observation in the postoperative period of an abnormal flow of digestive fluid through the abdominal drain orifice and/or the surgical wound [2-4, 7, 12]. In our context, in the absence of means of exploration of the fistula tract, the ileal or colonic origin of the fistula is often determined according to the nature of the discharge. Signs of dehydration, malnutrition, anemia and infection are often present in all patients and their degree depends on the importance of the fistula output as well as the associated comorbidities. In our series, 11 patients (15.94%) were HIV positive and 5 cases (7.25%) were diabetic.

The therapeutic management of postoperative enterocutaneous fistulas is quite complex and still very difficult in a disadvantaged surgical environment like ours. Drugs like somatostatin known to reduce the fistula output is not available in our hospital; and, parenteral nutrition is a major handicap considering the low socioeconomic status of most of our patients in Africa [3]. Indeed, while it is true that the ultimate goal in fistula management is to restore intestinal transit integrity and allow enteral feeding while minimizing morbidity and mortality [13]; initial treatment should focus on correction of fluid and electrolyte imbalance, drainage of collections, treatment of sepsis, and control of fistula flow [11, 14, 15]. This non-operative approach has the advantage

in some circumstances of leading to spontaneous closure of the fistula with rates ranging from 26 to 80% [1-4, 6, 12]. It should be noted that methods such as injection of fibrin or glue into the fistula pathway in order to obtain closure have been reported but not yet validated by a randomized prospective study [1]. The time to spontaneous closure is variable: it was 23 days in our cohort compare to the 32 days reported by Noori IF et al [16].

Re-intervention to heal the fistula is often indicated in situations of high output, persistence of the fistula, intra-abdominal sepsis or associated evisceration [2-6, 12]. The best time to perform this surgical procedure remains controversial. However, it is recommended to wait 4-6 weeks with the hope of spontaneous closure; and in cases of persistent fistula, to proceed to surgical repair [17].

Overall, the management of postoperative fistulas is associated with considerable mortality, particularly in resource-limited settings where death rates of 10-68% have been recorded [1-6, 17]. And surgical repairs are more prone to high morbidity and mortality [18-20]. Also, the occurrence of this complication significantly increases the length and cost of hospital stay, and patient's suffering [1-4, 21].

5. Conclusion

In conclusion, postoperative enterocutaneous fistula is a severe complication whose management in our environment is difficult and hopeless. Actually, in the absence of effective resuscitation and nursing, patients with high flow fistula deteriorate rapidly. Attempts to surgically close the fistula often fail and lead to further complications with a high mortality rate. The improvement of the prognosis requires continuous training of the surgeons and a better regulation of the surgical practice in our country.

Conflict of Interest

The authors declare that they have no competing interests.

References

- [1] Wereka J, Cagol PP, Melo ALP et al Epidemiology and outcome of patients with postoperative abdominal fistula *Rev col Bras Cir* 2016; 43 (2): 117-123.
- [2] Cisse M, Toure AO, Seck M et al Prise en charge des fistules entéro-cutanées post-opératoires au service de chirurgie générale du CHU A Le Dantec. *Rev Afr Chir* 2013; 7 (3): 5-9.
- [3] Eni UE, Gali BM Aetiology, management and outcome of enterocutaneous fistulas in Maiduguri, Nigeria. *Nigeria Journal of Clinical Practice* 2007; 10 (1): 47-51.
- [4] Kumar P, Maraju NK, Kate V Enterocutaneous fistulae: Etiology, treatment, and outcome - A study from South India. *Saudi J Gastroenterol* 2011; 17: 391-5.
- [5] Kathryn L, Galie MD, and Charles B, Whitlow MD Postoperative enterocutaneous fistula: when to reoperate and how to succeed *Clinics in Colon and Rectal Surgery* 2006; 19 (4): 237-246.
- [6] Mohanty SK, Mohanty R Evaluation and management of post-operative enterocutaneous fistula. *Ann. Int. Med. Den. Res.* 2017; 3 (4): sg01-sg04.
- [7] Haffejee AA Surgical management of high output enterocutaneous fistulae: a 24-year experience. *Curr Opin Clin Nutr Metab Care* 2004; 7: 309-316.
- [8] Alvarez C, Mcfadden DW, Reber HA Complicated enterocutaneous fistulas: failure of octreotide to improve healing. *World J Surg* 2000; 24: 533-538.
- [9] Makhdoom ZA, Komar MJ, Still CD Nutrition and enterocutaneous fistulas. *J Clin Gastroenterol* 2000; 31: 195-204.
- [10] Memon AS, Siddiqui FG Causes and management of postoperative enterocutaneous fistulas. *J Coll Physicians Surg Pak* 2004; 14: 25-28.
- [11] Hollington P, Mawdsley J, Lim W, Gabe SM, Forbes A, Windsor AJ An 11-year experience of enterocutaneous fistula. *Br J Surg* 2004; 91 (12): 1646-51.
- [12] Sulea EA, Nzegwub MA, Okoloc JC, Onyemekheiad RU Postoperative enterocutaneous fistula - principles in non-operative approach *Annals of Medicine and Surgery* 2017; 24: 77-81.
- [13] Evenson AR, Fischer JE Current management of enterocutaneous fistula. *J Gastrointest Surg* 2006; 10: 455-464.
- [14] Lloyd DAJ, Gabe SM and Windsor ACJ Nutrition and management of enterocutaneous fistula *British Journal of Surgery* 2006; 93: 1045-105.
- [15] Martinez JL, Luque-de-Leon E, Mier J et al Systematic management of postoperative enterocutaneous fistulas: factors related to outcomes. *World J Surg* 2008; 32: 436-443.
- [16] Noori IF Postoperative enterocutaneous fistulas: Management outcomes in 23 consecutive patients. *Annals of Medicine and Surgery* 2021; 66 (5): 102413; doi: 10.1016/j.jamsu.2021.102413.
- [17] Wainstein DE, Tungler V, Ravazzola C, Chara O Management of external small bowel fistulae: challenges and controversies confronting the general surgeon. *Int J Surg* 2011; 9: 198-203.
- [18] Schein M What's new in postoperative enterocutaneous fistulas? *World J Surg* 2008; 32 (3): 336-338.
- [19] Schecter WP, Hirshberg A, Chang DS et al Enteric fistulas: principles of management. *J Am Coll Surg* 2009; 209 (4): 484-491.
- [20] Connolly PT, Teubner A, Lees NP, Anderson ID, Scott NA, Carlson GL Outcome of reconstructive surgery for intestinal fistula in open abdomen. *Ann Surg* 2008; 247 (3): 440-444.
- [21] Lauro A, Cirochi R, Cautero N et al. Surgery for post-operative entero-cutaneous fistulas: is bowel resection plus primary anastomosis without stoma a safe option to avoid early recurrence? Report on 20 cases by a single center and systematic review of the literature. *G Chir* 2017; 38 (4): 185-198.