

Clinical and Histopathological Aspects of Acute Appendicitis at the Ignace Deen National Hospital of Conakry, Guinea

Naby Laye Youssouf Camara, Saa Yawo Kondano, Naby Fofana, Louncény Konate, Boubacar Barry, Alsény Diallo, Labilé Togba Soumaoro*, Aboubacar Toure, Aissatou Taran Diallo

Department of General Surgery, Ignace Deen National Hospital, Conakry, Guinea

Email address:

soumaoro66@gmail.com (L. T. Soumaoro)

*Corresponding author

To cite this article:

Naby Laye Youssouf Camara, Saa Yawo Kondano, Naby Fofana, Louncény Konate, Boubacar Barry, Alsény Diallo, Labilé Togba Soumaoro, Aboubacar Toure, Aissatou Taran Diallo. Clinical and Histopathological Aspects of Acute Appendicitis at the Ignace Deen National Hospital of Conakry, Guinea. *Journal of Surgery*. Vol. 10, No. 3, 2022, pp. 101-103. doi: 10.11648/j.js.20221003.11

Received: April 13, 2022; **Accepted:** April 27, 2022; **Published:** May 12, 2022

Abstract: *Purpose:* Acute appendicitis represents the most frequent surgical emergency in digestive surgery. The aim of this study was to describe the clinical and histological aspects of acute appendicitis at the Ignace Deen National Hospital in Conakry (Guinea). *Method:* This was a prospective study of a period of 6 months, from September 1 to December 31, 2020. All patients admitted and operated on in the department for acute appendicitis and whose surgical specimen was histologically examined were included in this study. *Results:* During the six months of the study, we collected 123 cases of acute appendicitis, i.e. 34.3% of the total surgical activity of the department. The average age of the patients was 17.50 ± 11.30 years. The female gender was the most predominant (69%). The diagnosis was essentially clinical. Appendectomy was performed in all patients by conventional approach. Laterocacral topography was the most frequent (43.09%) followed by pelvic (26.01%). In 57.6% of cases it was a cathartic appendicitis and 9% of cases were normal appendicitis. The overall mortality was 2.44%. *Conclusion:* Acute appendicitis is the most common indication for emergency abdominal surgery worldwide. Its clinical diagnosis remains sometimes difficult and source of multiple controversies because of the absence of anatomical parallelism.

Keywords: Acute Appendicitis, Diagnosis, Treatment, Histopathology

1. Introduction

Acute appendicitis represents the most frequent surgical emergency in digestive surgery [1]. The incidence of acute appendicitis has been declining steadily since the late 1940s. In developed countries, acute appendicitis occurs at a rate of 5.7–50 patients per 100,000 inhabitants per year, with a peak between the ages of 10 and 30 [1, 2].

The clinical diagnosis is sometimes difficult and a source of multiple controversies due to the absence of anatomical parallelism linked to the polymorphism of the lesions and the variations in anatomical positions [3].

Appendectomy is not a simple procedure. Mortality and morbidity vary between 5 and 30%, sometimes requiring a prolonged hospital stay or reoperation [4].

In our context, appendicitis is still wrongly considered as a

common pathology and appendectomy as a small surgery without scientific interest. This explains the scarcity of clinical and histopathological data and publications on this condition in Guinea. The aim of this study was to describe the clinical and histological aspects of acute appendicitis at the Ignace Deen National Hospital, Conakry (Guinea).

2. Patients and Methods

This was a prospective study of a period of 6 months, from September 1 to December 31, 2020. All patients admitted and operated on in the department for acute appendicitis and whose surgical specimen was histologically examined were included in this study. The variables studied were epidemiological, clinical, therapeutic and anatomopathological. Our data were analyzed by the Epi-info

software in its version 7.0. Qualitative data were presented in terms of frequency or percentage and quantitative data were evaluated as an average.

3. Results

During the study period, we collected 123 cases of acute appendicitis, i.e. 34.3% of all surgical activities in the department. The mean age of the patients was 17.50 ± 11.30 years with extremes of 7 and 70 years. The female gender was the most predominant (69%). The functional signs were dominated by pain in the right iliac fossa (100%). Physical examination revealed right iliac fossa tenderness in all patients. Fever was noted in 70 cases (56.91%). Neutrophilic hyperleukocytosis in 83 patients (67.48%). Abdominal ultrasonography contributed to the diagnosis in 49 cases (39.84%) by showing an increase in the diameter of the appendix and a liquid effusion in the right iliac fossa. Appendectomy was performed in all patients by conventional approach (laparotomy). Table 1 shows the topography of the appendix and Figure 1 shows the distribution according to the histological findings. The postoperative course was simple in 106 cases (86.18%). We recorded 14 cases (11.38%) of surgical site infection, and four cases (3.25%) of caecal fistula. The overall mortality was 2.44% (n=3).

Table 1. Distribution of patients according to the topography of the appendix.

Topography	Number	Percentage
Latero-caecal	53	43,09
Pelvic	32	26,01
Meso celiac	23	18,70
Retro caecal	15	12,20
Total	123	100

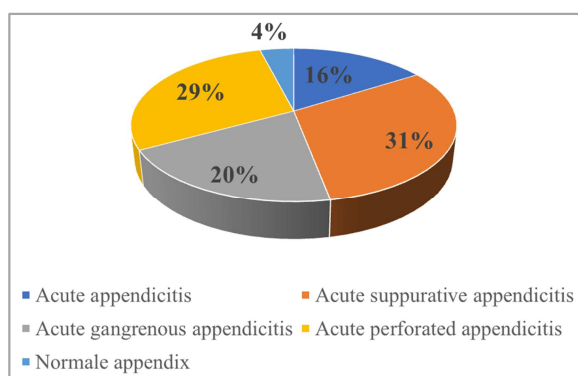


Figure 1. Distribution of patients according to histopathological type.

4. Discussion

Acute appendicitis is the most common surgical emergency [1, 2]. It is the most common indication for emergency abdominal surgery worldwide: approximately one in every ten individuals will have acute appendicitis during their lifetime [5]. In the surgical setting, learners make the appendectomy an ultimate goal that must be achieved quickly regardless of the indication. It is a disease of the young

subject. The predominance of females in our series could be explained by the interventionist approach to any pain of the right iliac fossa in young girls. Moreover, there is great variation in the presentation, severity of the disease, radiological findings, and surgical management of patients having acute appendicitis that is related to country income [6]. Indeed, in our context, the inaccessibility of imaging examinations (ultrasound and CT scan) added to the surgeon's fear of allowing appendicitis to develop into complications could explain this interventionist approach. Despite this, the diagnosis of appendicitis is usually made at the stage of complications, particularly in children [4, 7-9]. These children often waste time in pediatric wards where they are treated for either intestinal parasitosis or gastroenteritis until signs of complications from appendicitis develop.

In our environment, the diagnosis of appendicitis is essentially clinical. The blood cell count and blood count sometimes show hyperleukocytosis and help to orient the diagnosis. In equipped hospitals, the use of ultrasound, CT or MRI can avoid unnecessary interventions [10, 11].

Since surgeons started performing appendectomies in the nineteenth century, surgery has been the most widely accepted treatment, with more than 300,000 appendectomies performed annually in the USA [5]. Current evidence shows laparoscopic appendectomy (LA) to be the most effective surgical treatment, being associated with a lower incidence of wound infection and post-intervention morbidity, shorter hospital stays, and better quality of life scores when compared to open appendectomy (OA) [12, 13]. However, in our context, the lack of equipment and the inexperience of surgeons make open appendectomy the only surgical technique.

Despite the limitations of available studies, some authors have provided valuable evidence regarding the outcomes of antibiotic first versus immediate surgery for acute non-perforated appendicitis [14]. In the absence of adequate means of surveillance (ultrasound, CT), immediate surgery is preferable in the case of any suspicion of appendicitis in order to avoid the occurrence of complications that could jeopardize the patient's vital prognosis.

Acute appendicitis in laterococcal position was the most frequent topographic form and acute appendicitis was present in 16%. The evolution of this anatomopathological aspect remains very much debated. It is not certain that these lesions evolve into complicated forms [15]. As the appendix is in continuity with the cecum, it is not uncommon for certain debris to cause an exudate in the appendicular lumen by mechanical effect and induce the presence of an inflammatory infiltrate in the mucosa. Acute appendicitis can therefore be considered as a reactive appendix within the histological limits of normal [16].

Confirmation of acute appendicitis is histological, which makes anatomopathological examination essential whatever the macroscopic aspect of the appendix, it allows to objectify inflammatory lesions specific to other pathologies, to make the incidental discovery of tumors and to adapt the treatment,

This examination also makes it possible to review the operative indications in order to considerably reduce abusive appendectomies. In this series, we noted 4% of normal appendix. Unfortunately, in our environment, although appendectomy is commonly and abundantly performed, the rate of realization of the anatomopathological examination is still very low even in university hospitals.

The mortality rate was 2.44% in our study. This relatively low rate is consistent with the literature [5]. These deaths are attributable to postoperative septic complications, of which caecal fistula remains the most formidable and the most difficult to manage in resource-limited surgical settings.

5. Conclusion

Acute appendicitis constitutes the most frequent surgical emergency with a female predominance in our department. Its clinical diagnosis remains sometimes difficult and source of multiple controversies because of the absence of anatomic and clinical parallelism. Rigor in the operative indications and in the performance of the anatomopathological examination could help to reduce the rate of abusive appendectomy and to detect lesions specific to benign or malignant conditions. The data from this study should encourage us to undertake a larger study. The training of the staff and the equipment of our hospitals in laparoscopic surgery could considerably improve the prognosis of this condition.

Conflict of Interest

The authors declare that they have no competing interests.

References

- [1] Cervellin G, Mora R, Ticinesi A, et al. Epidemiology and outcomes of abdominal pain in a large urban Emergency Department: retrospective analysis of 5,340 cases. *Ann Transl Med.* 2016; 4: 362.
- [2] Ilves I. Seasonal variations of acute appendicitis and nonspecific abdominal pain in Finland. *WJG.* 2014; 20: 4037.
- [3] Kharmakhem R, Boukedi A, Rahay H et al Apport de l'échographie abdominale dans la prise de décision thérapeutique devant une symptomatologie appendiculaire chez l'enfant. A propos de 266 cas. [Contribution of abdominal ultrasonography in therapeutic decision making in the face of appendicular symptomatology in children. About 266 cases]. *Journal de pédiatrie et de puériculture* 2013; 26: 36-37.
- [4] Ndour O, Faye Fall A, Mbaye PA, Ndoeye NA, Seck NF, Ngom G, Ndoeye M. Complications de l'appendicectomie chez l'enfant. [Complications of appendectomy in children]. *Rev Afr Chir Spéc* 2015; 1: 18-23.
- [5] Addiss DG, Shaffer N, Fowler BS, Tauxe RV. The epidemiology of appendicitis and appendectomy in the United States. *Am J Epidemiol* 1990; 132: 910-925.
- [6] Gomes CA, Abu-Zidan FM, Sartelli M, et al. Management of Appendicitis Globally Based on Income of Countries (MAGIC) Study. *World J Surg.* 2018; 42: 3903-10.
- [7] Ngowe M, Bissou Mahop J, Atangana R, Eyenga VC, Pisoh-Tangnym C and Sosso AM Aspects cliniques actuels des appendicites aiguës de l'adulte à Yaoundé, Cameroun. *Bull Soc Pathol Exot*, 2008; 101 (5): 398-399.
- [8] Touré A, Ngowé M, Touré FB et al Prise en charge des complications post opératoires précoces des appendicectomies dans le service de chirurgie générale de l'Hôpital National Ignace Deen du CHU de Conakry. [Management of early postoperative complications of appendectomies in the general surgery department of the Ignace Deen National Hospital of Conakry.]. *J Afr Chir Digest* 2013; 13 (1): 1431-1434.
- [9] Soumaoro LT, Touré A, Mamy GF, Diallo IS, Bah IB, Diallo AT Péritonite appendiculaire: fréquence et prise en charge dans le service de chirurgie générale de l'hôpital national Ignace Deen de Conakry (Guinée). [Appendicular peritonitis: frequency and management in the general surgery department of the Ignace Deen National Hospital in Conakry, Guinea]. *Médecine d'Afrique Noire* 2019; 66 (2): 86-90.
- [10] Espejo OJA, Mejia MEM, Guerrero LHU Acute appendicitis: imaging findings and current approach to diagnostic images. *Rev Colomb Radiol* 2014; 25 (1): 3877-88.
- [11] Leite NP, Pereira JM, Cunha R, Pinto P and Sirlin C CT evaluation of appendicitis and its complications: imaging techniques and key diagnostic findings. *AJR* 2005; 185 (2): 406-417.
- [12] Jaschinski T, Mosch C, Eikermann M, et al. Laparoscopic versus open appendectomy in patients with suspected appendicitis: a systematic review of meta-analyses of randomised controlled trials. *BMC Gastroenterol.* 2015; 15: 48.
- [13] Yu M-C, Feng Y, Wang W, et al. Is laparoscopic appendectomy feasible for complicated appendicitis? A systematic review and meta-analysis. *Int J Surg.* 2017; 40: 187-97.
- [14] Sallinen V, Akl EA, JYoun JJ. Meta-analysis of antibiotics versus appendectomy for non-perforated acute appendicitis *BJS* 2016; 103: 656-667.
- [15] Akbulut S, Tas M, Sogutcu N, Arikanklu Z, Basbug M, Ulku A et al Atypic histopathologic findings in appendix *Gastroenterologia* 2011; 17 (15): 1961-70.
- [16] Thiam I, Doh K, Dial C, Agbobli M, Diop M, Woto-Gaye G. Étude nécropsique de 100 appendices au Sénégal [Necropsy study of 100 appendages in Senegal]. *J. Afr. Hépatol. Gastroentérol.* DOI 10.1007/s12157-015-0643-3.