

# Duodenal Intussusception Secondary to Brunner's Gland Hamartoma: Case Report

Adolfo Leyva-Alvizo<sup>1, \*</sup>, Jose Emmanuel Martínez-Escalante<sup>2</sup>, Cristina Villar-Canton<sup>3</sup>,  
Diana Paola Padilla-Armendariz<sup>3</sup>

<sup>1</sup>Surgery Department, Tecnológico de Monterrey, Monterrey, Mexico

<sup>2</sup>Surgical Oncology Department, Institute of Social Security of Mexico State, Toluca, Mexico

<sup>3</sup>School of Medicine, Tecnológico de Monterrey, Monterrey, Mexico

## Email address:

adolfoleyva@gmail.com (A. Leyva-Alvizo)

\*Corresponding author

## To cite this article:

Adolfo Leyva-Alvizo, Jose Emmanuel Martínez-Escalante, Cristina Villar-Canton, Diana Paola Padilla-Armendariz. Duodenal Intussusception Secondary to Brunner's Gland Hamartoma: Case Report. *Journal of Surgery*. Vol. 10, No. 3, 2022, pp. 117-120. doi: 10.11648/j.js.20221003.15

Received: April 29, 2022; Accepted: May 12, 2022; Published: May 24, 2022

---

**Abstract:** Brunner's glands are submucosal glands found in the duodenum. When they proliferate, they can lead to the formation of hamartomas, they are a rare cause of benign lesions of the duodenum. The aim of the article is to present a case of a Brunner gland hamartoma, which was surgically approached due to obstructive symptoms, in addition to showing apparent images of intussusception on the abdominal tomography.

**Keywords:** Duodenal Intussusception, Duodenal Hamartoma, Duodenal Tumor

---

## 1. Introduction

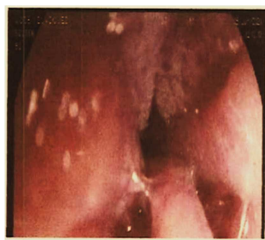Brunner's glands Hamartoma (BGH) of the duodenum is a very rare pathology. It is considered approximately as 10% of benign neoplasms of the duodenum, normally found in a pedunculated form. Up to 57% are found in the duodenal bulb, and the percentage decreases towards the following portions of it. They are usually asymptomatic lesions, found as an incidental finding during endoscopic studies. Sometimes, when they are larger lesions, considered giant (larger than 5 cm), they can cause symptoms. Usually presented with abdominal pain, nausea, vomiting, hematochezia or melena, obstruction, and rarely, even intussusception. When this pathology begins to cause symptoms, it is treated by definitive resection of the lesion, either by endoscopic or surgical treatment [1].

We present the case of a Brunner's glands Hamartoma, which was treated surgically due to obstructive symptoms, in addition to showing apparent images of intussusception in the abdominal tomography, which subsequently presented a satisfactory evolution.

## 2. Case Report

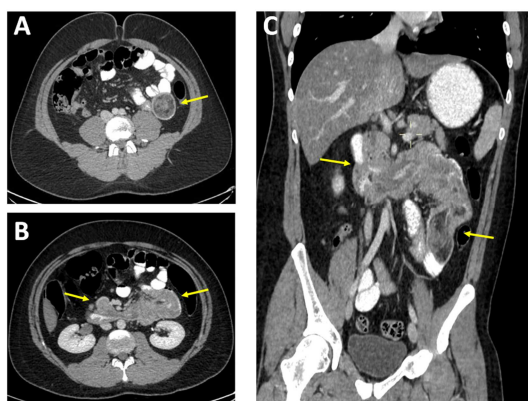
27-year-old male with no relevant medical history for his current condition. Current condition began one month prior to admission, presenting as insidiously burning abdominal pain of moderate intensity, located in the epigastrium, intermittent, aggravated by food intake, without mitigating factors and accompanied by abdominal distension. It progressed until 4 hours before admission with an increase in pain intensity, adding nausea and vomit of gastric content, so he decided to seek for medical evaluation and management. Upon arrival, vital signs were within normal parameters. On physical examination, abdomen was distended, with decreased peristalsis, soft, depressible, and painful on palpation in the epigastrium, without data of peritoneal irritation. Laboratories were taken, finding iron deficiency anemia and a thrombophilia of 529,000. An upper abdominal ultrasound was performed, which showed only moderate hepatic steatosis. An upper endoscopy was performed, which reported an extrinsic inflammatory process of unknown origin that hinders passage to the second portion of the

duodenum, with an apparent polyp in the topography of the ampulla of Vater (Figure 1).



**Figure 1.** Proceso inflamatorio extrínseco de origen a determinar que dificulta el paso hacia la segunda porción del duodeno, con aparente pólipo en la topografía del ámpula de váter.

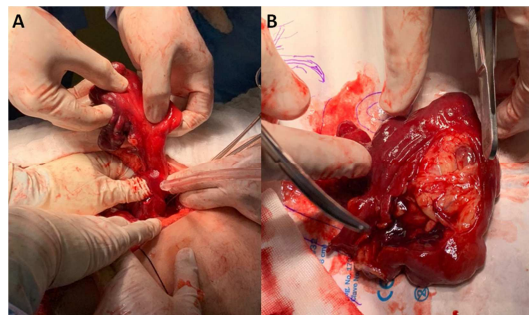
Performing contrast-enhanced computer Tomography (CECT) was decided to complement the study of the abdomen. A filiform passage was observed at the level of the second and third portions of the duodenum due to thickening of the mucosa, probable edema with a polypoid lesion that extended to the jejunum, heterogeneous with negative densities, considering probable intussusception at this level (Figure 2).



**Figure 2.** Tomografía de abdomen contrastado. Paso filiforme del material de contraste a nivel de la segunda y tercera porción del duodeno por engrosamiento de la mucosa, probable edema con lesión poliploide que se extiende hasta el yeyuno, se señala en amarillo la intususcepción (A) corte transversal A nivel de segunda porción del duodeno, (B) corte transversal a nivel de tercera y cuarta porción del duodeno, (C) corte coronal.

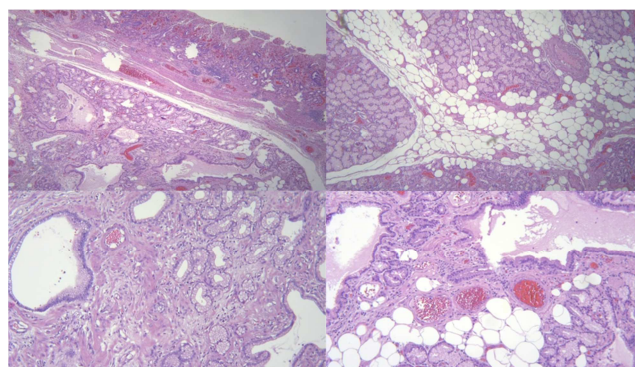
Given the findings described in both endoscopy and CT, added to the persistence of symptoms, it was decided to schedule the patient for surgery. A diagnostic laparoscopy was performed, where a very dilated small intestine was evidenced due to a probable chronic obstructive process. Without being able to evidence laparoscopically the presence of masses or intussusception it was converted to an exploratory laparotomy. A tumor was palpated at the level of the proximal jejunum. An enterotomy was performed in the jejunum at 30cm from the angle of Treitz, evidencing a tumor dependent on the mucosa and submucosa without differentiating its apparent origin. In addition, a lymph node of 4x3cm was found, which was dissected and sent for intraoperative biopsy, reporting a probable low-grade lymphoma. Due to suspicion of a duodenal origin of the

tumor, the retroperitoneum was approached. Upon reaching the second portion of the duodenum, an umbilication of its outer wall was noted. A duodenotomy was performed and a tumor dependent on the duodenum was exteriorized, with sites of caseated tissue and necrosis, approximately 10x5cm (Figure 3).



**Figure 3.** Tumorción dependiente de duodeno, con sitios de tejido caseificado y necrosis, de aproximadamente 10x5cm. (A) Vista lateral, (B) vista superior.

The tumor was resected with subsequent closure of the enterotomies in two layers, with 3-0 vicryl in Connel-Mayo running suture, and subsequently Lembert stitches with 3-0 silk. Fibrin glue was placed over the intestinal closure. Intraoperative endoscopy was performed where the site of the enterotomy was visualized with fully approximated borders, without data of active bleeding, also a pneumatic test was performed without finding data of leakage. 2 Blake-type drains were placed, the right one destined for duodenal enterotomy and the other left for jejunal enterotomy. The laparotomy wound was closed with barbed monofilament 0 suture and the subcutaneous cellular tissue was closed with 3-0 vicryl. Finally, the skin was closed with staples. The patient fasted for 3 days, fed initially by IV nutrition. At 4th day he then was started on a diet, which progressed from a liquid to normal. The final pathology report revealed a Brunner's gland hamartoma (lesion 7.1 x 3.1 x 1.6cm) (Figure 4). The patient was discharged after 10 days of hospital stay without complications.



**Figure 4.** Lesión constituida por una proliferación de glándulas mucosas revestidas por células claras, de citoplasma vacuolado y núcleos basales, sin datos de atipia están dispuestas en un patrón lobular, con dilatación de algunas glándulas; se observan conductos grandes, hay lóbulos de tejido adiposo maduro. La lesión esá bien limitada, con bordes de resección viables. No se observaron datos de displasia, ni evidencia de malignidad.

### 3. Discussion

Brunner's glands were first described in 1688 by the Swiss anatomist Conrad Brunner. They are located mainly in the submucosa of the duodenum, decreasing towards the ampulla of Vater. They secrete alkaline fluid which can help prevent gastric acid from eroding the duodenal epithelium [2, 3].

Among the benign lesions of the Brunner's glands are hyperplastic nodules, polyps, or hamartomas. Some describe that a lesion smaller than 2cm is defined as a hyperplastic nodule or polyp, while lesions larger than 2cm carry the term of hamartoma [4, 5].

They represent 5 to 10% of benign tumors that can be in the duodenum, with an incidence of less than 0.01%. A hamartoma consists of observing an abnormal proliferation of Brunner's glands, in addition to finding a mixture of adipose tissue, fibrous septa, smooth muscle, and other components of normal tissue [6–8].

These lesions usually present as a polyp or pedunculated mass with normal mucosa on its surface, their distribution throughout the small intestine decreases with its advance, from 70% in its proximal portion, decreasing in frequency throughout the rest of the small intestine. Specifically in duodenum, 57% are found in the duodenal bulb, 27% in the second portion, 5% in the third [1].

The exact etiology is not clear yet, but chronic pancreatitis and *Helicobacter pylori* are considered to play a role in its presentation. In a study of 19,000 people, 5 out of 7 of whom were diagnosed with Brunner's gland hamartoma also had *H. pylori* infection [3, 9, 10].

Its nomenclature may seem confusing when searching the literature. Based on the perspective of histopathology, some consider that a lesion smaller than 5mm in size, whether solitary or multiple, is a hyperplasia, while when it is larger than this size it is called a hamartoma. This is important, since size is a parameter that is considered to define the type of management that will be given, since it has been seen that large and solitary lesions are more likely to cause symptoms [11].

These types of lesions are found as an incidental finding during an endoscopic study of the upper gastrointestinal tract. Speaking of hamartoma, which is a rare benign tumor of the duodenum, at endoscopy it is found as a submucosal mass that may have a pedicle. They are generally asymptomatic, but may present with bleeding, intestinal obstruction, or insidiously with symptoms such as dyspepsia or anemia. [11–13].

Gastrointestinal symptoms that may occur are abdominal pain, as an initial symptom, abdominal distension, diarrhea, and hematochezia. In a study of 27 cases, 37% presented with bleeding, 37% with intestinal obstruction and the rest were incidental findings. When performing imaging studies such as CT, Brunner's gland hyperplasia is commonly found as a solitary or multiple lesion smaller than 5mm. The hamartoma is larger than this, commonly small, on average approximately 2 cm, with internal cysts in a third of the cases. Up to 83% of the cases are visualized as iso-attenuated image compared to the pancreas in a CT scan without contrast, and

as hypo-attenuated image after the administration of iodinated contrast in half of the cases. An enhanced border at the periphery of the lesion can be observed during the visible arterial phase in two thirds of the studies. In some studies, it has been observed that Ultrasound and CT have rates of up to 100% of diagnosis [8, 13, 14].

When performing an MRI, internal images of a cystic appearance can be observed in a hamartoma, which are hyperintense in T2. Treatment in asymptomatic cases is conservative, while symptomatic cases are treated by resection, either under endoscopic treatment when they are small or surgically when they are large (>5cm) usually for bleeding, obstruction or intussusception. Recurrence has been very rarely described in the literature, it is not considered a malignant pathology, so its removal can be considered successful with an excellent long-term prognosis [1, 15, 16].

### 4. Conclusions

In this case we can conclude that, despite being a rare cause, we must take this type of injury into account when addressing this type of symptomatology, or when studying anemias with no apparent origin. It is although infrequent, something that could produce upper GI symptoms, or that may require close follow up if it is found as an incidental finding (asymptomatic) to avoid complications. It is important to know this pathology to avoid an erroneous diagnosis since this pathology is not commonly thought of as one of the first differential diagnoses when evaluating a patient with these characteristics. After treatment, no cases reporting malignancy have been published and it is rare that recurrence has occurred.

### References

- [1] Kostalas M, Jackson P, Karanjia N. Brunner's gland hamartoma: a cause of the double-duct sign. *Ann R Coll Surg Engl.* 2016 Jul; 98 (6): e92–3.
- [2] Gao Y-P, Zhu J-S, Zheng W-J. Brunner's gland adenoma of duodenum: a case report and literature review. *World J Gastroenterol.* 2004 Sep; 10 (17): 2616–7.
- [3] Tan Y-M, Wong W-K. Giant Brunneroma as an unusual cause of upper gastrointestinal hemorrhage: report of a case. *Surg Today.* 2002; 32 (10): 910–2.
- [4] Kim K, Jang SJ, Song HJ, Yu E. Clinicopathologic characteristics and mucin expression in Brunner's gland proliferating lesions. *Dig Dis Sci.* 2013 Jan; 58 (1): 194–201.
- [5] Collins K, Ligato S. Duodenal Epithelial Polyps: A Clinicopathologic Review. *Arch Pathol Lab Med.* 2019 Mar; 143 (3): 370–85.
- [6] Abbass R, Al-Kawas FH. Brunner gland hamartoma. *Gastroenterol Hepatol (N Y).* 2008 Jul; 4 (7): 473–5.
- [7] BOTSFORD TW, CROWE P, CROCKER DW. Tumors of the small intestine. A review of experience with 115 cases including a report of a rare case of malignant hemangio-endothelioma. *Am J Surg.* 1962 Mar; 103: 358–65.

- [8] Levine JA, Burgart LJ, Batts KP, Wang KK. Brunner's gland hamartomas: clinical presentation and pathological features of 27 cases. *Am J Gastroenterol*. 1995 Feb; 90 (2): 290–4.
- [9] Lee JH, Jo KM, Kim TO, Park JH, Park SH, Jung JW, et al. Giant Brunner's Gland Hamartoma of the Duodenal Bulb Presenting with Upper Gastrointestinal Bleeding and Obstruction. *Clin Endosc*. 2016 Nov; 49 (6): 570–4.
- [10] Kovacević I, Ljubicić N, Cupić H, Doko M, Zovak M, Troškot B, et al. *Helicobacter pylori* infection in patients with Brunner's gland adenoma. *Acta Med Croatica*. 2001; 55 (4-5): 157–60.
- [11] Patel ND, Levy AD, Mehrotra AK, Sobin LH. Brunner's gland hyperplasia and hamartoma: imaging features with clinicopathologic correlation. *AJR Am J Roentgenol*. 2006 Sep; 187 (3): 715–22.
- [12] Stermer E, Elias N, Keren D, Rainis T, Goldstein O, Lavy A. Acute pancreatitis and upper gastrointestinal bleeding as presenting symptoms of duodenal Brunner's gland hamartoma. *Can J Gastroenterol*. 2006 Aug; 20 (8): 541–2.
- [13] Sun J-G, Qi J, Yang B, Gao Y, Huang J-J, Zhao C. The clinical characteristics and treatment of intestinal hamartomas. *Lasers Med Sci*. 2016 Dec; 31 (9): 1761–6.
- [14] Hur S, Han JK, Kim M-A, Bae J-M, Choi BI. Brunner's gland hamartoma: computed tomographic findings with histopathologic correlation in 9 cases. *J Comput Assist Tomogr*. 2010 Jul; 34 (4): 543–7.
- [15] Takeuchi M, Cho H, Sugimoto M, Ohira T, Usuki N, Morimoto Y. CT and MRI findings for Brunner's gland hamartoma: report of three cases. *Jpn J Radiol*. 2015 Jun; 33 (6): 375–9.
- [16] Yamauchi K, Iwamuro M, Ishii E, Narita M, Hirata N, Okada H. Gastroduodenal Intussusception with a Gastric Gastrointestinal Stromal Tumor Treated by Endoscopic Submucosal Dissection. *Intern Med*. 2017; 56 (12): 1515–9.