

Case Report

Walled-off Pancreatic Necrosis Treated with Video-Assisted Retroperitoneal Debridement (VARD)

Gustavo Adolfo Guerrero Martínez, Luis Gerardo Aguilera Muñoz, Maryel Sánchez Olvera

General Surgery Service, Hospital Regional ISSSTE, Puebla, Mexico

Email address:

dr.guerreroam@yahoo.com.mx (Gustavo Adolfo Guerrero Martínez), luisgera.m@gmail.com (Luis Gerardo Aguilera Muñoz), maryel.sanchezo@gmail.com (Maryel Sánchez Olvera)

To cite this article:

Gustavo Adolfo Guerrero Martínez, Luis Gerardo Aguilera Muñoz, Maryel Sánchez Olvera. Walled-off Pancreatic Necrosis Treated with Video-Assisted Retroperitoneal Debridement (VARD). *Journal of Surgery*. Vol. 10, No. 5, 2022, pp. 144-148. doi: 10.11648/j.js.20221005.11

Received: March 21, 2022; **Accepted:** April 11, 2022; **Published:** September 29, 2022

Abstract: Acute pancreatitis is Pancreas inflammatory process that should be suspected in patients with severe acute abdominal pain in the upper quadrants, mainly in the epigastrium. However, to diagnose it, laboratory and imaging studies are necessary and two of the following criteria are required: abdominal pain consistent with the disease, serum amylase or lipase elevated more than three times the upper limit of normal and strongly suggestive images (US, CT, MRI). Up to 10-20% of cases of severe pancreatitis will develop necrosis of the gland and its peripheral tissues, generating a slow and torpid evolution with tendency to clinical deterioration, carrying the patient to mortality of up to 20-40% when associated with infection. In these cases, an invasive approach is mandatory in order to extract the fluid from inside the collection and/or necrotic tissue. Minimally invasive techniques such as percutaneous or endoscopic drainage, endoscopic necrosectomy, and video-assisted pancreatic necrosectomy (VARD) have been proposed, due to the high rate of morbidity and mortality that open necrosectomy carries; however, it is still used when minimally invasive management does not solve the problem. In this article we present the case of a 56-year-old patient with moderate acute pancreatitis of biliary origin, complicated by infected pancreatic necrosis, being managed with VARD, presenting an adequate postoperative evolution.

Keywords: Acute Pancreatitis, Pancreatic Necrosis, Percutaneous Drainage, Necrosectomy, VARD, Minimally Invasive, Peripancreatic Collections

1. Introduction

Acute pancreatitis (AP) is an inflammatory process of the pancreas that should be suspected in patients with severe acute abdominal pain in the upper abdomen. However, to make the diagnosis, laboratory and imaging studies are necessary and two of the following criteria are required: Abdominal pain consistent with disease, elevated serum pancreatic enzymes (amylase and lipase) greater than three times the upper normal limit, and strongly suggestive imaging by ultrasonography (USG), computed tomography (CT), or magnetic resonance imaging (MRI) [1].

According to the Atlanta guidelines, AP can be classified as follows: Mild AP in which there is no organ failure and no local or systemic complications; Moderate AP in which organ failure is present but resolves in less than 48 hours and may or

may not have local complications; and severe AP which presents persistent organ failure (more than 48 hours) [2].

The main causes of acute pancreatitis are gallstones and alcohol consumption [3].

Most of the cases are mild or moderate, with self-limitation of the damage, evolving adequately. However, 10-20% of cases are associated with necrosis of the pancreatic gland, peripancreatic tissues, or both. If this occurs, patients have a slow and insidious clinical course, with associated mortality of up to 20-40% when infection is added [4, 5].

The gold standard for the diagnosis of acute necrotizing pancreatitis is tomography with intravenous contrast, it allows evaluating the extent of necrosis and suspecting the presence of infected necrosis, which represents an indication for intervention. Collections or walled necrosis can also be observed, where there may be gas bubbles caused by bacteria or by the formation of

spontaneous fistulas from the necrotic cavity to the intestinal lumen (pathognomonic sign of infection) [3, 6].

In severe acute pancreatitis, interventions should be avoided for the first two weeks, which is the time necrosis should be expected to be well organized, generally occurring three to five weeks after symptoms disappear [7-9].

Walled necrosis is described as an encapsulated pancreatic or peripancreatic collection that is presented 4 weeks after the onset of necrosis. Approximately 15% of patients with severe pancreatitis develop walled-off necrosis. Of these, 50% will be asymptomatic and will present spontaneous resolution [10].

When the infected necrosis diagnosis is not very clear, a fine needle aspiration can be performed to confirm it, however, there are up to 20% false negatives in the results, in most cases clinical and imaging studies are sufficient for diagnosis [3].

It is generally accepted that the treatment of pancreatic necrosis based on drainage or debridement is indicated in patients with infection due to the high risk of mortality that it entails. This may also be required in cases of sterile collections or necrosis with persistent symptoms (abdominal pain, nausea, vomiting and nutritional disorders) or associated complications such as gastrointestinal obstruction, biliary obstruction, recurrent pancreatitis, fistulas or persistent Systemic Inflammatory Response Syndrome (SIRS) [4, 11].

2. Clinical Case

A 56-year-old female, with long-standing systemic arterial hypertension, without other comorbidities, who presented acute pancreatitis of biliary origin and acute cholecystitis,

To whom an open cholecystectomy and exploration of the bile ducts was performed, reporting 200cc of hematic liquid in cavity, pancreas with increased volume and consistency, and saponification of peripancreatic fats, a T-tube was placed (whit no further findings commented). She was sent to Hospital Regional ISSSTE Puebla to monitor postoperative convalescence, evolving without major complications, being discharged 6 days after her entry, with the following laboratories: leukocytes 15300 cells/mcl, neutrophils 82%, hemoglobin 11 g/dl, hematocrit 31.3%, platelets 173 thousand/mcl, PT 16.4 sec, INR 1.16, PTT 26.8 sec, glucose 162 mg/dl, urea 10.7 mg/dl, creatinine 0.4 mg/dl, BUN 5 mg/dl, sodium 132 mmol/l, potassium 3.19 mmol/l, chloride 99 mmo/l. Chest computed tomography (CT) had findings consistent with CORADS 3 being assessed by the internal medicine service who recommended out-of-hospital management with indomethacin and clarithromycin. Pleural effusion of approximately 20% was also evidenced, which is why invasive management was not started and discharge was decided.

Two weeks after hospital discharge, she began with intermittent epigastric pain, of mild to moderate intensity, predominantly postprandial, generating partial intolerance to the oral route, progressing to nausea and emesis. The pain progressively increased in intensity and became more constant, radiating to the left lumbar region, accompanied by unquantified weight loss, reason of her reentry to the

emergency room. Laboratory studies reporting leukocytes 10,800 cells/mcl, neutrophils 80%, hemoglobin 11.4 g/dl, hematocrit 34.7%, platelets 520,000/mcl, glucose 223 mg/dl, urea 50.1 mg/dl, creatinine 0.8 mg/dl, BUN 23.4 mg/dl, sodium 122 mmol/l, potassium 4.5 mmol/l, chlorine 82 mmol/l, amylase 24.5 U/l, lipase 12.3 U/l, PT 16.4 sec, INR 1.16, PTT 27.2 sec, BT 0.79 mg /dl, BD 0.55 mg/dl, BI 0.24 mg/dl, TGO 17 U/l, TGP 11 U/l, AF 131 U/l, highlighting moderate hyponatremia as the only abnormality. Abdominopelvic CT with oral contrast was performed showing abundant gas in pancreatic topography, and free perihepatic fluid, deciding admission to general surgery due to suspected infected pancreatic necrosis.

During her hospitalization, a nasojunal tube was placed for enteral nutrition and a 12Fr percutaneous drainage catheter guided over the left lumbar region, obtaining very viscous and mucopurulent fluid. 10 days later, VARD was performed under general anesthesia. An oblique incision was made superior to the previously placed catheter, placing it in the right lateral decubitus position, dissecting by planes following the catheter's path, through the intercostal muscles and retroperitoneum, abording the pancreatic cell, finding necrosis of 100% of the pancreatic gland, still preserving its architecture, we also found thrombosis of pancreatic vessels. The pancreatic cell was covered with fibrosis with no evidence of active infection of surrounding tissues or evidence of fistulas. There was little non-fetid reaction fluid. A 12mm trocar was placed and, under direct vision, it was washed and aspirated, and with the help of a ring forceps, the entire pancreatic gland was pulled and removed. The cell was irrigated with 3L warm saline solution 0.9%, remains of detritus were removed, leaving the cell clean and little layer bleeding, hemostasis was performed with hydrogen peroxide and one ¼ drenovac drainage was placed for the postsurgical control; fascia and skin closure was performed, going on to recovery without major complications during extubation.

Enteral diet was restarted in the immediate postoperative period in a progressive manner, tolerating it adequately, monitoring was maintained for 12 days, during which only 2 days were irrigated, since the output gradually lightened and decreased; The drainage was accidentally removed on postoperative day 9. She was maintained under surveillance for 3 more days without further incidents. She did not present data of systemic inflammatory response or clinical deterioration. Her laboratories remained within normal parameters, opting for an outpatient follow up.

3. Discussion

The general management of patients with pancreatic necrosis includes adequate fluid resuscitation, antibiotics if sepsis or clinical deterioration is demonstrated, and nutritional support. Infected necrosis is suspected when pancreatic or peripancreatic collections with gas are demonstrated or if patients present fever, bacteremia, leukocytosis with an increasing tendency, persistent malaise or clinical deterioration, however, the prophylactic administration of antibiotics does not show an impact on the

development of infection, systemic complications, mortality or the need for surgical intervention. Prolonged fasting alters the integrity of the intestinal mucosa with the subsequent increase in bacterial translocation, which significantly increases the risk of infection of pancreatic necrosis (20% in patients receiving enteral nutrition vs 47% patients receiving parenteral nutrition), for that reason enteral nutrition should be given if possible (as early as the first 24-72 hours) [3, 4, 12].

Multiple approaches are described for the management of pancreatic and peripancreatic collections and necrosectomies. Initially, open procedures were described, which were performed early, however, high rates of bleeding and colonic or pancreatic fistulas were observed, leading to perioperative morbidity of 50-60% and mortality of 20-25%. Less invasive procedures such as percutaneous drainage (PD), endoscopic transgastric necrosectomy (NTE), and video-assisted retroperitoneal debridement (VARD) were later described. The step up approach includes the use of these techniques serially to avoid open management as much as possible [5, 9, 13].

There are different approaches for the management of peripancreatic collections or to perform necrosectomy, which are divided into open, endoscopic and minimally invasive procedures.

3.1. Percutaneous Drainage

It can be used to decompress retroperitoneal fluid collections and allows stabilization of patients with sepsis prior to surgical debridement. Its success rate is 50-80%, with a morbidity rate of 30-40% and it has been shown that 35% of patients with necrotic collections will not require subsequent interventions. After placement, catheters may be irrigated with isotonic solutions and serial imaging performed to assess changes in dimension and density of the collections and ensure patency of the catheter lumen. Small diameter drains are expanded to larger caliber catheters to remove necrotic debris [3, 7, 14].

It is also used to establish percutaneous access to collections using the transperitoneal route or as a guide for subsequent minimally invasive surgical debridement in patients who are too unstable. Left retroperitoneal access is preferred, facilitating necrosectomy if required later [4, 6, 9].

A disadvantage is that all mechanical debridement and tissue evacuation must be performed through catheters of limited diameter, requiring frequent replacement and meticulous maintenance. There is also risk of persistent pancreaticocutaneous fistula, which is why the use of endoscopic transgastric drainage is sometimes preferred, or the combination of percutaneous drainage with the latter [4, 8].

3.2. Endoscopic Drainage and Necrosectomy

It is typically performed through a transgastric or transduodenal approach, depending on the region where the largest collection is found (at the level of the pancreatic head, a transduodenal approach is recommended, in the rest it is better transgastric). The puncture site is identified by locating a bulge in the gastrointestinal. The collection is entered, and a

fluid sample is aspirated for Gram stain and culture. The use of endoscopic ultrasound is recommended to locate collections adequately, assess its content, measure the distance to the intestinal lumen, avoid vascular injury, and distinguish the collection from other structures such as the gallbladder. Two catheters are placed to perform continuous irrigation after drainage. If there is no evident improvement at 72 hours, endoscopic transluminal necrosectomy (ENT) is performed, dilating the cystogastrostomy, under direct vision the loose necrotic tissue is removed by combining irrigation, traps, baskets and extraction balloons, leaving again 2 catheters to continue irrigations, which may include antibiotics or hydrogen peroxide [9].

The endoscopic technique provides a targeted approach to focal pancreatic necrosis reducing systemic inflammatory response, progression to multiple organ failure, and avoiding the wound complications associated with major laparotomy incisions. Its main disadvantage is the difficulty in completely debriding the necrosis that involves the paracolic space. Its success rate is reported up to 81%, defining it as successful management and clinical recovery only with this method. Complications are reported in up to 36%, these are bleeding (18%), pancreatic fistula (5%), visceral perforation (4%) and very rarely air embolism. Percutaneous and endoscopic approaches can be combined to improve efficacy. Mortality has been reported as high as 6% [3, 15, 16].

3.3. Video-Assisted Retroperitoneal Debridement (VARD)

Surgical debridement's objectives are to control the origin of the infection, reduce the necrotic load and, at the same time, in highly compromised patients produce the least metabolic response to trauma [4].

It is a minimally invasive technique that has reported a similar success rate to open and complete debridement can be achieved. Lateral approach is ideal for necrosis that extends into the left paracolic space. Its main complication is the formation of a pancreatic fistula. It is indicated in patients with infected pancreatic necrosis with more than 4 weeks of evolution in whom the stepped approach (percutaneous or endoscopic drainage) has been initiated. Its contraindications are hemodynamic instability, anterior location of the necrosis, its extension into the right paracolic space, or suspicion of visceral perforation [11, 14, 16].

It requires the placement of a percutaneous access in the retroperitoneal space guided by image. A 12 or 14 French catheter is placed into the dominant fluid collection through a direct access site in the left upper quadrant or flank. This catheter provides an anatomical access route that will guide the approach. Under general anesthesia, the patient is placed in right lateral decubitus or supine position with the left flank elevated 30-40 degrees. A subcostal incision of approximately 5 cm is made in the left flank at the level of the midaxillary line, near the exit site of the percutaneous drainage and it is dissected bluntly guided by it until the collection is found. Purulent material is aspirated and necrotic material is removed with the help of wide forceps, irrigation and suction. To prevent bleeding, it is only removed the tissue that gently sheds. To facilitate

vision a 12mm trocar can be inserted and the cavity is insufflated with CO₂, direct vision can be made with a 0-degree lens. The catheter used as a guide is removed and 2 large-caliber drains are placed in the cavity to perform postoperative lavage, from 125 ml/hr to 10 liters of isotonic solution in 24 hours. Patients are followed for clinical progression, decreased serum C-reactive protein (CRP) levels, and improvement of necrosis on contrast-enhanced CT scans. If necessary, repeated debridements are performed every 7 to 10 days until the cavity is observed to be free of necrosis and/or debris and lined with healthy granulation tissue. At this point, irrigation is stopped and external drainages continued until outflow stops and the catheters can be removed [7, 11, 15].

The advantage of this approach is that it allows drainage of necrosis and accumulated fluid without contaminating the abdominal cavity, it also allows placing drainages to continue postoperative treatment. It has not shown superiority compared with the open technique in patients in whom percutaneous drainage has failed, however, it reduces the rate of incisional hernias, new-onset diabetes, late postoperative use of pancreatic enzymes, and multiple organ failure, it also reduces treatment costs [3, 16].

Its main drawbacks are restricted access and visualization, which limits the amount of removable tissue and leads to multiple interventions. Its success rate is 60-70%, with 50% morbidity and 15-20% mortality. Its major complications are persistent sepsis, need for another intervention, bleeding and pancreatic fistula [14].

3.4. Open Proceedings

The indications for open surgery are persistent sepsis after a minimally invasive intervention, complications such as bleeding or intestinal perforation. This type of procedures are associated with high rates of complications (34-95%) and mortality (11-39%) with risks of chronic pancreatic insufficiency [3, 6].

With external drainage: A bilateral subcostal or upper midline incision is made, the retroperitoneum is accessed, fluid is evacuated, and debridement is initiated by pulling loosely organized debris away from firm, inflamed and viable tissue by blunt dissection. Viable tissue should be preserved and can be identified by its firm, indurated appearance and consistency, as well as bleeding on manipulation. Major vascular structures are characteristically well preserved, allowing careful skeletonization during debridement. Once the main cavity is debrided, any extension of the process is identified by gentle digital palpation exploring the communicating spaces and extensions of necrosis throughout the retroperitoneum. Debridement often extends to the fat of the mesocolon or the mesentery of the bowel. Care must be taken to avoid vascular injury, particularly to the superior or inferior mesenteric vessels. In this approach, a cholecystectomy can be performed in patients with biliary pancreatitis. The need for intraoperative cholangiography will depend on whether endoscopic retrograde cholangiopancreatography (ERCP) was performed prior to surgery. If necessary, a gastrojejunal feeding tube can be

placed, two to four large closed suction drains are placed. It presents an operative morbidity of 72% and mortality in 4%; the average length of hospital stay is 26 days [4].

With internal drainage and cystogastrostomy: This procedure is only appropriate for patients with walled-off pancreatic necrosis. Surgery is performed through a midline incision, a longitudinal gastrotomy is performed along the greater curvature, and the posterior gastric wall is exposed. A needle is used to identify the walled pancreatic collection posterior to the stomach. The cavity is opened with cautery and a wide cystogastrostomy (at least greater than 8 cm) is performed, debridement, a nasogastric tube is placed into the cavity, a gastrostomy drain is placed, and the gastrostomy is closed. The nasogastric tube is then flushed with isotonic saline every four hours for two to three days. The cystogastrostomy has the potential to be a wide enteric drainage in case the patient evolves with a pancreatic fistula due to section of the main pancreatic duct [4].

3.5. Laparoscopic Drainage

Various techniques are described from transabdominal catheter-guided approach, single port access to hand-assisted procedures. The most used is the transabdominal access similar to the one described in the open procedure. Cystogastrostomy is performed with endoscopic staplers. Transmesocolic debridement can also be performed, using a video camera port and two additional working ports. The main disadvantage of this approach is the possibility of peritoneal contamination. Reoperation is not common due to scar tissue, so it is more appropriate as a single-stage procedure for patients with walled-off pancreatic necrosis [15].

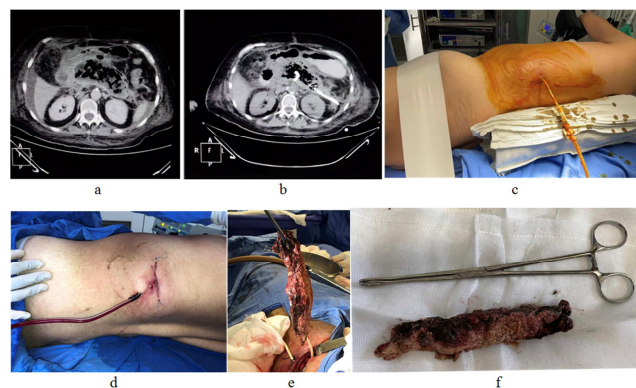


Figure 1. a. Admission CT; b. CT post percutaneous drainage; c. Presurgical position; d. Post-surgical wound and drainage; e and f. Surgical piece (necrotic pancreas).

4. Conclusion

It was presented the first case of a patient with walled-off pancreatic necrosis successfully managed with a stepped approach, culminating with the VARD technique, in Hospital Regional ISSSTE Puebla, with certain modifications of the techniques described by other authors, dispensing with a catheter for postoperative irrigation, using only one for irrigation and suction, having a rapid and satisfactory

evolution. There are cases in which, despite minimally invasive management, there are complications or persistence of the collections, so multiple approaches must be taken into account, in which it is preferred a step up approach, without ruling out the need open drive.

References

- [1] Velázquez de la Vega R, Cárdenas Lailson LE. Pancreatitis aguda y necrosis pancreática: conceptos actuales y tratamiento. *Cirujano General*. 2017; 39 (3): 147-51.
- [2] Ortiz Morales CM, Parlorio de Andrés E, Olalla Muñoz JR, Girela Baena JA, López Corbalán JA, Murcia ES. La clasificación de Atlanta revisada en imágenes. En Congreso SERAM 2014; 2014.
- [3] Hackert T, Büchler MW. Decision Making in Necrotizing Pancreatitis. *Dig Dis*. 2016; 34 (5): 517-24.
- [4] H. Baron T, J. DiMaio C, Y. Wang A, a: Morgan K. American Gastroenterological Association Clinical Practice Update: Managment of Pancreatic Necrosis. *AGA*. 2020; 158: 66-75.
- [5] Sorrentino L, Chiara O, Mutignani M, Sammartano F, Brioschi P, Cimbanassi S. Combined totally mini-invasive approach in necrotizing pancreatitis: a case report and systematic literature review. *World J Emerg Surg*. diciembre de 2017; 12 (1): 16.
- [6] van Santvoort HC, Bakker OJ, Dejong CH, Schaapherder AF, Bollen TL, Nieuwenhuijs VB, et al. A Step-up Approach or Open Necrosectomy for Necrotizing Pancreatitis. *The New England Journal of Medicine*. 2010; 12.
- [7] Logue JA, Carter CR. Minimally Invasive Necrosectomy Techniques in Severe Acute Pancreatitis: Role of Percutaneous Necrosectomy and Video-Assisted Retroperitoneal Debridement. *Gastroenterology Research and Practice*. 2015; 2015: 1-6.
- [8] John BJ, Swaminathan S, VenkataKrishnan L, Singh GS, Krishnaveni G, Mohandas N, et al. Management of Infected Pancreatic Necrosis—The “Step Up” Approach and Minimal Access Retroperitoneal Pancreatic Necrosectomy. *Indian J Surg*. abril de 2015; 77 (S1): 125-7.
- [9] The Dutch Pancreatitis Study Group, van Brunschot S, van Grinsven J, Voermans RP, Bakker OJ, Besselink MG, et al. Transluminal endoscopic step-up approach versus minimally invasive surgical step-up approach in patients with infected necrotising pancreatitis (TENSION trial): design and rationale of a randomised controlled multicenter trial [ISRCTN09186711]. *BMC Gastroenterol*. diciembre de 2013; 13 (1): 161.
- [10] Dalsania R, Willingham FF. Treatment of walled-off pancreatic necrosis. *Current Opinion in Gastroenterology*. septiembre de 2019; 35 (5): 478-82.
- [11] Zhang J, Sun B. Comparison between video-assisted retroperitoneal debridement and small incision pancreatic necrosectomy in infected pancreatic necrosis. *ANZ Journal of Surgery*. octubre de 2020; 90 (10): 2020-5.
- [12] Bendersky V, Mallipeddi M, Perez A, Pappas T. Necrotizing pancreatitis: challenges and solutions. *CEG*. octubre de 2016; Volume 9: 345-50.
- [13] Karakayali FY. Surgical and interventional management of complications caused by acute pancreatitis. *WJG*. 2014; 20 (37): 13412.
- [14] Sánchez-Gálvez MÁ, Martínez-Baena D, Parra-Membrives P, Jiménez-Riera G, Lorente-Herce JM. Video-assisted retroperitoneal debridement (VARD). 2018; 3.
- [15] Hollemans RA, van Brunschot S, Bakker OJ, Bollen TL, Timmer R, Besselink MG, et al. Minimally invasive intervention for infected necrosis in acute pancreatitis. *Expert Review of Medical Devices*. noviembre de 2014; 11 (6): 637-48.
- [16] Fagenholz PJ, Thabet A, Mueller PR, Forcione DG. Combined endoscopic transgastric drainage and video assisted retroperitoneal pancreatic debridement – The best of both worlds for extensive pancreatic necrosis with enteric fistulae. *Pancreatolgy*. septiembre de 2016; 16 (5): 788-90.