



Osteoplastic Orbitotomy for Surgical Treatment of Isolated Orbital Tumors

Anton Kalinovskiy^{1,2,*}, Ekaterina Balkhanova¹

¹Department of Neurosurgery №4 (Oncological), Federal Center of Neurosurgery, Novosibirsk, Russian Federation

²Department of Neurosurgery, Novosibirsk State Medical University, Novosibirsk, Russian Federation

Email address:

akalinovsky1980@gmail.com (Anton Kalinovskiy), balkkatya@yandex.ru (Ekaterina Balkhanova)

*Corresponding author

To cite this article:

Anton Kalinovskiy, Ekaterina Balkhanova. Osteoplastic Orbitotomy for Surgical Treatment of Isolated Orbital Tumors. *Journal of Surgery*. Vol. 11, No. 2, 2023, pp. 55-59. doi: 10.11648/j.js.20231102.14

Received: December 29, 2022; **Accepted:** April 26, 2023; **Published:** May 10, 2023

Abstract: Orbital tumors are a difficult pathology for surgical removal and are additionally complicated by the issue of selecting a proper surgical approach. Currently, the choice of approach remains debatable for the surgical treatment of orbital tumors. This paper presents a retrospective analysis of 26 patients with isolated orbital tumors who were operated on in our neurosurgical center from 2012 till 2020. The series included 15 female and 11 male patients, whose age varied from 3 to 75 years. The most common symptoms of lesions were exophthalmia (20 pts), retrobulbar pain (15 pts) and visual disorders (6 pts). In all the considered cases, the tumors were removed via osteoplastic orbitotomy. 12 patients (46%) had a tumor in either central or lateral location, 5 (20%) – in superior location, 5 (20%) – in inferior location. 24 tumors (92%) were removed totally and 2 tumors (8%) – were removed subtotally. More than 70% of the treated tumors comprised hemangiomas, pseudotumors and tear-gland tumors. 18 patients preserved their acuity at the preoperative level; 6 patients improved their visual function; visual function degraded in 2 patients. Orbitotomy has proven to be an effective technique in the removal of the most of isolated intraorbital tumors excluding those of medial location.

Keywords: Isolated Orbital Tumors, Osteoplastic Orbitotomy, Orbital Tumor Removal

1. Introduction

The orbital bone is a complex region at the boundary of the skull's cranial and facial segments and nasal cavity that embraces a lot of anatomical structures of different histological nature such as vessels, nerves, periorbital fibers, an eye bulb, muscles and a tear gland.

The frequency of primary orbital tumors is at least 1 per 100000 people per year [1]. Dermoid cysts and cavernous hemangiomas prevail among benign tumors, and non-Hodgkin lymphomas - among malignant tumors [2].

Surgical treatment of orbital tumors located posteriorly to the eye bulb is a complex issue. Anatomical features, free space packed with periorbital fat and a large number of functionally important structures significantly complicate surgical manipulations in this region, and intraoperative damage done to the surrounding anatomical structures leads to such rough consequences as dry eyes, diplopia, reduced or

lost vision and even removal of the eye ball.

Currently, there have been a large number of approaches devised for the surgical treatment of orbital tumors. While anterior tumor locations call for simple orbitotomy, tumors located in the middle and posterior parts of the orbit (retrobulbar location) require extended approaches involving different kinds of orbital-wall and cranial orbitotomies [3, 4]. The latter, in its turn, can be divided into two groups: simple osteoplastic orbitotomy without dural exposure and transcranial approaches that form a classical craniotomy with exposure of the dura.

Osteoplastic orbitotomy was introduced by Rudolf Krönlein [5] in 1889 and has been used ever since. In 1922, Walter Dandy published a paper in which he described an orbital tumor removal via subfrontal intradural craniotomy followed by osteoplastic orbitotomy [6]. Currently, an approach is selected based on tumor location [7], and the efficacy and safety of different techniques is still vividly discussed. Most authors suggest using lateral orbitotomy only

for a small group of tumors located in the lateral parts of the orbit, while tumors located in the superior or superior-medial parts of the orbit are recommended to be removed via the fronto-orbital approach. For tumors localized in the inferior parts of the orbit, the pterional or orbitozygomatic approaches [8, 9] are recommended.

The objective of the present paper is to analyze the surgical treatment results of orbital tumors of different localizations via osteoplastic orbitotomy.

2. Materials and Methods

Retrospective analysis of the clinical manifestations and surgical treatment results for patients with orbital tumors was performed. Only patients with isolated orbital tumors with no signs of intracranial or intranasal proliferation were included in the analysis. From 2013 to 2020, 26 of such patients were operated on to treat primary orbital tumors. In all these cases, the tumors were removed via osteoplastic orbitotomy. Selecting the type of orbitotomy depended on the tumor location. Upon admission, all patients underwent contrast-enhanced MRI brain examination; local status assessment; vision and ocular-mobility exam; exophthalmia degree and dynamics estimation. The series included 15 female and 11 male patients, whose age varied from 3 to 75 years (mean 44.8 ± 22 yrs).

The complaints the patients had upon admission were exophthalmia (20 pts), retrobulbar pain (15 pts), visual disorders (6 pts, including amaurosis on the afflicted side in 2 pts and significantly reduced eyesight in 4 pts). In 13 patients, the tumor was detected on the left side, and in another 13 – on the right side. The patients' data are presented in Table 1.

Table 1. Patient data.

Number of patients	26
Gender, male/female	11/15
Mean age	44.8±22
Afflicted side, left/right	13/13
Symptoms	
Proptosis	20
Oculomotor disorders	7
Retrobulbar pain	15
Headache	10
Moderate eyesight reduction (down to 0.1)	14
Significant eyesight reduction (below 0.1)	4
Amaurosis	2

All patients underwent osteoplastic orbitotomy. The type of procedure performed depended on intraorbital tumor localization. The procedure's radicality was estimated using contrast-enhanced MRI brain examination within 24 hours after the procedure. In addition, the patients' visual and oculomotor functions were assessed postoperatively.

The results of the preoperative contrast-enhanced MRI brain examination were used to determine tumor localization relative to the muscle cone and optic nerve. Depending on the lesion's primary location, the tumors were divided into superior, lateral+central and inferior. Most of them were

found in the lateral+central (46%) and superior (34%) regions of the orbit, making the inferior location the rarest of the three (20%). As for the muscle cone, most of the tumors were found inside of it (77%, see Table 2).

Table 2. Tumor localization relative to the muscle cone and optic nerve.

Relative to the optic nerve:	
Lateral + central	12 (46%)
Superior	9 (34%)
Inferior	5 (20%)
Relative to the muscle cone:	
Intraconal	20 (77%)
Extraconal	6 (23%)

3. Surgical Technique

The surgical procedures were performed in a supine position, with the patient's head being fixed with a Mayfield clamp on the side opposite to the afflicted one. Neuronavigation was used preoperatively to localize the lesion and determine approach trajectory and orbitotomy volume (Figure 1).

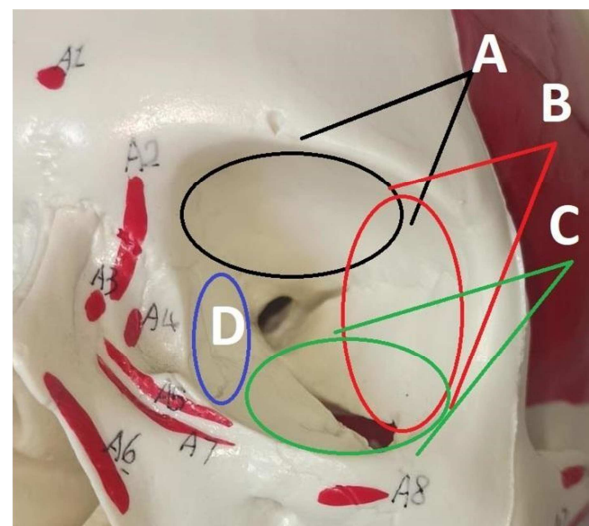


Figure 1. Performed orbitotomy type depended on tumor localization inside the orbit.

Primarily, lateral or central tumors were targeted using lateral orbitotomy (B); for superior or superior-medial localizations, orbitotomy of the superior-lateral and superior regions was performed (A); for inferior and inferior-medial localizations, inferior-lateral (C) orbitotomy was carried out. Skin incision was put along the middle and lateral third of the brow and laterally 1-2 cm along the orbit's edge. A dissector was used to separate periosteum and periorbita in the projection of the orbitotomy, which was performed using a craniotome. The average size of the trepanation window comprised 2 *2 cm. When operating in the superior orbital regions, the dura was not exposed. After removing the bone flap, periorbita was exposed in the projection of the most superficial part of the tumor relative to the trepanation window. An operating microscope was applied to identify, expose and remove the tumor, preserving the healthy tissues.

After the removal, the bone flap was returned to its place using a titanium plate and screw fixation. Stitching the incision was performed following the standard techniques.

4. Results

More than 70% of the treated tumors comprised hemangiomas, pseudotumors and tear-gland tumors. Their detailed description and histological composition are given in Table 3.

Table 3. Histology of the treated orbital tumors.

Histology	Number	%
Cavernous hemangioma	10	38.4
Inflammatory pseudotumor	5	19.3
Tear-gland tumor	4	15.5
Meningioma	2	7.8
Hemangiopericytoma	1	3.8
Schwannoma	1	3.8
Dermoid cyst	1	3.8
Pilocytic astrocytoma	1	3.8
Osteoma	1	3.8
Total	26	100

A total removal was achieved in 24 cases (92.3%), and subtotal – in 2 cases (7.7%). In the first case, the nonradicality was due to optic-nerve and oculomotor- muscle involvement, and in the second – due to the tumor's infiltrative proliferation into the retrobulbar region.

As for visual function preservation, postoperative examination showed that 18 patients preserved their acuity at the preoperative level; 6 patients improved their visual function, and in 2 patients, visual function degraded. In the first patient with pilocytic astrocytoma such reduction in visual function had been expected, while the second had developed a meningioma that covered optic nerve like a sleeve, making its non-traumatic exposure impossible. Progressing oculomotor disturbances in the early postoperative period were observed in 6 patients, which was due to the traction put on the muscles and nerves placed in the retrobulbar region (Table 4). These disturbances completely disappeared in all patients during the follow-up period. 18 patients retained the symptoms they had before the operation. One patient had previously been operated on for an orbital tumor earlier. An unsuccessful attempt at transconjunctival removal of the tumor had been made in a local ophthalmology clinic that resulted in injury to the conjunctiva which was treated with sutures, as a result the rough scar adhesion prevented the patient from proper recovery.

Table 4. Radicality degree and complications.

Radicality:	
Total	24
Subtotal	2
Additional neurological deficiency:	
Oculomotor dysfunction	6 (100% regress in late postoperative period)
Visual acuity reduction	2
Intraoperative conjunctiva damage	1

5. Clinical Case

A male patient of 73 years was admitted in our center with complaints of right eyeball protrusion, pain in the right eye, lacrimation and diplopia. Since the symptoms had been around for a year, a local ophthalmologist had performed a needle biopsy to detect the presence of inflammation in the retrobulbar fibers.

To determine the causes of progressing symptoms and increasing exophthalmia, a contrast-enhanced MRI brain examination was carried out which revealed an extensive clear-contoured contrast-absorbing neoplasm of 29x20x19 mm in the right orbit located interconally, and laterally relative to the optic nerve. The tumor compressed the eye bulb dislocating it anteriorly, medially and inferiorly to reduce the visual acuity to OD/OS – 0.6/0.7.

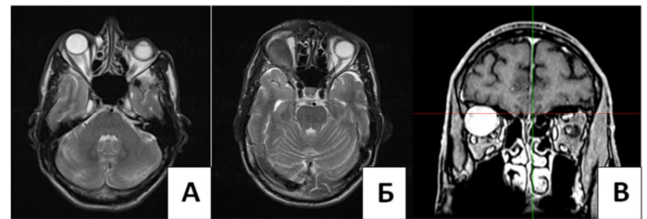


Figure 2. Post-contrast brain MRI images detecting an extensive right-orbit neoplasm.

The patient underwent lateral osteoplastic orbitotomy to remove the tumor. The bone flap was installed in its place and fixed there using plates and miniscrews (Figure 3). The operation time comprised 1 hour and 50 minutes, the blood loss was 50 ml.

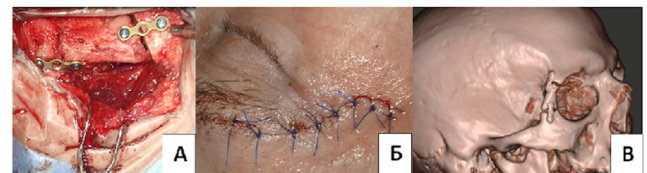


Figure 3. Intraoperative images (A and B) demonstrating the size and shape of orbitotomy, and incision localization; 3D skull reconstruction (C) showing craniotomy localization next to the orbit's lateral wall.

Both exophthalmia and diplopia regressed in the postoperative period, while visual acuity did not change. Contrast-enhanced MRI imaging showed no sign of residual tumor (Figure 4).

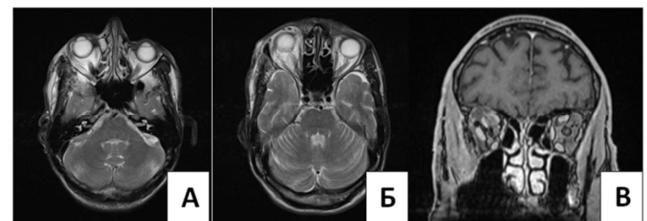


Figure 4. Patient's contrast-enhanced MRI images obtained in 24-hours post right-sided osteoplastic orbitotomy.

6. Discussion

Surgery of orbital tumors has been an issue of multi-disciplinary discussion for many years. While eyeball tumors localized in the anterior third of the orbit are operated by ophthalmologists, retrobulbar ones are treated by ophthalmologists, craniofacial surgeons and neurosurgeons. In most cases, retrobulbar tumors are removed via neurosurgical (transcranial) approaches that often require the zygomatic bone to be dissected (so-termed frontoorbital, frontozygomatic and fronto-orbitozygomatic approaches) [10-14]. According to the authors, these advanced transcranial approaches enable one to properly visualize the retrobulbar region and safely remove the tumor without excessive traction placed on the surrounding tissues. However, these approaches have a number of downsides, the most notably is their lengthening, which increases surgical trauma, the need to open the frontal sinus which increases the risk of infection and possible trauma to the dura that may provoke cerebrospinal fluid rhinorrhea. Lateral approaches such as frontotemporal approach require cutting and suturing of the temporalis muscle which may reduce its functionality and ruin the cosmetic result of the procedure. Transcranial approaches also call for lateral and superior orbital wall resection since bone-flap formation and depression of the dura from the abovementioned structures does not allow for proper visualization of the intraorbital regions [10]. Additionally, the authors mention a need for wide exposure of orbit, so intraorbital structures could be better visualized. They also mention a large number of limitations that orbitotomy has for isolated removal of an orbital tumor leading them to favor transcranial approaches for performing such removals. In their opinion, the main indication for lateral orbitotomy is tumor localization in the lateral regions of orbit [15].

In our patient series, we preferred osteoplastic orbitotomy as an alternative to the abovementioned transcranial approaches. Being minimally invasive, this technique does not require the resection of lateral and upper orbital bone structures. At the same time, the access formed after bone flap removal remains wide enough for proper visualization of retrobulbar structures starting from the eye bulb's posterior side up to the orbital tip. The type of approach depends on tumor localization (superior, medial or inferior orbital regions) and allows for less traumatic tumor removal without resorting to the extended and cranioorbital approaches.

7. Conclusion

Based on the 26 primary intraorbital tumors cases we believed that osteoplastic orbitotomy is effective and safe approach. Performing osteoplastic orbitotomy for the removal of retrobulbar tumors not proliferating beyond the orbit enables one to properly visualize the retrobulbar region and provide enough space for safe manipulations with tumor and surrounding muscles, nerves and orbital fibers. Analysis of preoperative MRI images for determining a tumor's

proliferation pattern and the way it interacts with the eye bulb, optical nerve and oculomotor muscles make it possible to select a surgical approach to match a patient's individual needs in terms of its type, size and shape. Osteoplastic orbitotomy spares orbital bone structures and can serve as an alternative to extended cranioorbital approaches for isolated orbital tumor removal. However, this approach has limitations in the localization of tumors in the medial parts of the orbit. Other approaches should be considered in these cases.

References

- [1] Markowski J. et al. Primary orbital tumors: A review of 122 cases during a 23-year period: A histo-clinical study in material from the ENT Department of the Medical University of Silesia // *Med. Sci. Monit.* 2014. Vol. 20. P. 988–994.
- [2] Bonavolontà G. et al. An analysis of 2,480 space-occupying lesions of the orbit from 1976 to 2011 // *Ophthalm. Plast. Reconstr. Surg.* 2013. Vol. 29, № 2. P. 79–86.
- [3] Khan, A. M., & Varvares, M. A. (2006). Traditional Approaches to the Orbit. *Otolaryngologic Clinics of North America*, 39 (5), 895–909. doi: 10.1016/j.otc.2006.08.008.
- [4] Cockerham, K. P., Bejjani, G. K., Kennerdell, J. S., & Maroon, J. C. (2001). Surgery for orbital tumors. Part II: transorbital approaches. *Neurosurgical Focus*, 10 (5), 1–6. doi: 10.3171/foc.2001.10.5.4.
- [5] Kronlein R. Zur pathologie und behandlung der dermoidcysten der orbita. *Beitr Klin Chir.* 1888; 4: 149.
- [6] Dandy W. E. Prechiasmal Intracranial Tumors of the Optic Nerves // *Am. J. Ophthalmol.* 1922. Vol. 5, № 3. P. 169–188.
- [7] Bejjani G. K. et al. A reappraisal of surgery for orbital tumors. Part I : extraorbital approaches // *Neurosurg. Focus*. 2001. Vol. 10, № 5. P. 1–6.
- [8] Montano N. et al. Orbital Tumors: Report of 70 Surgically Treated Cases // *World Neurosurg.* Elsevier Inc, 2018. Vol. 119. P. e449–e458.
- [9] Paluzzi A. et al. Round-the-clock surgical access to the orbit // *J. Neurol. Surgery, Part B Skull Base*. 2015. Vol. 76, № 1. P. 12–24.
- [10] Yoshihiro Numa, M.D., Ph.D. and Keiji Kawamoto, M.D., Ph.D. Frontozygomatic Approach to Intraorbital Tumors. *SKULL BASE/VOLUME 17, NUMBER 5*, 2007.
- [11] Nevo Margalit, M.D., Haim Ezer, M.D., Dan M. Fliss, M.D., Elvira Naftaliev, M.D., Erez Nossek, M.D., and Anat Kesler, M.D. Orbital tumors treated using transcranial approaches: surgical technique and neuroophthalmological results in 41 patients. *Neurosurg Focus* 23 (3): E11, 2007.
- [12] Ciappetta P, Delfini R. Surgical strategies in the treatment of symptomatic osteomas of the orbital walls. *Neurosurgery*. 1992 Oct; 31 (4): 628-34; discussion 634-5. doi: 10.1227/00006123-199210000-00003.
- [13] Fukushima T, Hirohita T. Surgical approach to the cavernous angioma of the orbit, with special reference to the orbital microsurgical anatomy. *Jpn J Neurosurg* 1998; 7: 609–61410.

- [14] Natori Y, Rhoton AL Jr. Transcranial approach to the orbit: microsurgical anatomy. *J Neurosurg* 1994; 81: 78–8611.
- [15] Kaywan Aftahy, MD, Philipp Krauss, MD, Melanie Barz, MD, Arthur Wagner, MD, Bernhard Meyer, MD, Chiara Negwer, MD, Jens Gempt, MD. Surgical treatment of intraorbital lesions. *World Neurosurgery* (2021), doi: <https://doi.org/10.1016/j.wneu.2021.09.011>.