

# Closure of Appendicular Stump Using Absorbable Polydioxnon Endoclips in Laproscopoic Appendictomy

Wael Barakaat Ahmed Mohamed, Ahmed Eisa Ahmed

Department of Surgery, Sohag University, Sohag, Egypt

**Email address:**

waelbarakaat1979@gmail.com (W. B. A. Mohamed)

**To cite this article:**

Wael Barakaat Ahmed Mohamed, Ahmed Eisa Ahmed. Closure of Appendicular Stump Using Absorbable Polydioxnon Endoclips in Laproscopoic Appendictomy. *Journal of Surgery*. Special Issue: Minimally Invasive and Minimally Access Surgery. Vol. 5, No. 3-1, 2016, pp. 8-11. doi: 10.11648/j.js.s.2017050301.12

**Received:** December 26, 2016; **Accepted:** December 27, 2016; **Published:** February 6, 2017

---

**Abstract:** *Background:* Since 1983 when the 1st laparoscopic appendectomy was described by Semms, different methods for closure of the appendicular stump during laparoscopic appendectomy such as linear stapler (Endo GIA), endoloop ligature, intracorporeal suture and metal endoclips were used. The use of non-absorbable plastic clips was described in several studies which reported the low cost and easy application of these clips. *Objective:* to evaluate the efficiency of closure of appendicular stump using polydioxanone AP 400 endoclips techniques as regard the intraoperative and postoperative complications. *Patients:* From October 2014 to October 2015, 40 patients from General surgery department Sohag university hospitals undergoing laparoscopic appendectomy with closure of appendicular stump using polydioxanone AP 400 endoclips was done for all the patients. *Primary outcome measures:* were feasibility of the clip, intra-abdominal surgical site (abscesses, stump leakages) and superficial wound infections. *Results:* The staples were applicable in nearly 80% of patients. Reasons for not applying the clip were mainly aninflamed caecum or a too large diameter of the appendix base. Superficial wound infections were found in two (5%), intra-abdominal abscesses in one (2.5%), no leak from the appendicular stump was detected. *Conclusions:* The results suggest that the polydioxanone endo clip is a safe and effective option in securing the appendicular stump in laparoscopic appendectomy.

**Keywords:** Appendicitis, Laparoscopic Appendectomy, Hem-o-Lock Clip, Appendicular Stump

---

## 1. Introduction

Appendectomy is the most commonly performed emergency operation worldwide. Since the introduction of laparoscopy, this minimally invasive technique was quickly adapted to appendectomy. Laparoscopic appendectomy has many advantages such as rapid postoperative recovery, good cosmetics, less wound complications, less postoperative pain [1]. A recent study comparing laparoscopic and open appendectomy show laparoscopic appendectomy had less postoperative pain, rapid postoperative recovery, shorter hospital stay, and fewer postoperative complications [2]. Laparoscopic appendectomy is more superior in complicated appendicitis without increase the risk of intra-abdominal abscess. This advantage has been shown by the systematic review of Markides G, et al [3]. it also has many other advantages such as the decrease the incidence of postoperative intestinal obstruction rate, this was reported by

Markar SR, et al. in their systematic review [4].

Since 1983 when the 1<sup>st</sup> laparoscopic appendectomy was described by Semms [5], different methods for closure of the appendicular stump during laparoscopic appendectomy such as linear stapler (Endo GIA) [6], endoloop ligature [7], intracorporeal suture and metal endoclips were used [8]. The use of non-absorbable plastic clips was described in several studies which reported the low cost and easy application of these clips [9, 10]. The aim of this work was to evaluate the efficiency of closure of appendicular stump using polydioxanone AP 400 endoclips [Abslock AP 400<sup>TM</sup>, Ethicon endo surgery, USA} techniques as regard the intraoperative and postoperative complications.

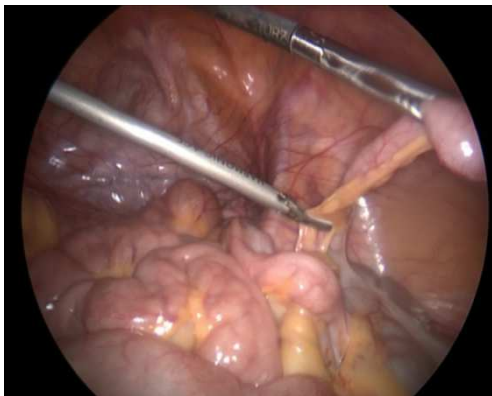
## 2. Patients and Methods

This prospective study was conducted From October 2014 to October 2015 in General surgery department Sohag

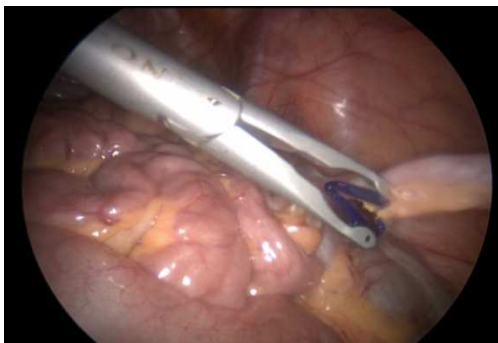
University Hospitals., Sohag, Egypt. A total of 40 patients undergoing laparoscopic appendectomy with closure of appendicular stump using polydioxanone AP 400 endoclips [Abslock AP 400TM, Ethicon endo surgery, USA} were included in this study. The study was approved by the Ethic Committee, board in Sohag University Hospitals. All patients had informed written consent prior to surgery.

### 3. Operative Technique

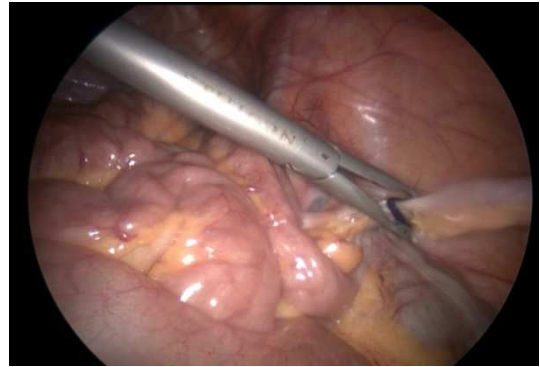
All procedures were done under general anesthesia with the patients in the supine position with the head down and right side up. A Foley catheter was routinely inserted. The monitor was on the right side and the surgeon and the assistant stood on the patients left side. Using verus needle pneumoperitoneum (14 mmHg) was created and after that introduction of 30 degree laparoscope through 12 mm supraumbilical port was done, one 10-mm port was inserted in the suprapubic area, and one 5-mm port was inserted in the right lower quadrant (at-McBurney's point). A suprapubic trocar was used as the main working port, and an additional trocar at the right iliac fossa was used as the auxiliary port. The mesoappendix was mobilized and resected with a harmonic scalpel (Ethicon Endo-Surgery Inc., Cincinnati, OH, USA). The proximal base of the appendix was closed using polydioxanone clipAP400 (Ethicon Endo-Surgery Inc., Cincinnati, OH, USA). and another clip was placed distally in the appendix, which was transected between the clips. The appendix was transected using the harmonic scalpel. The appendix was then removed through the suprapubic port.



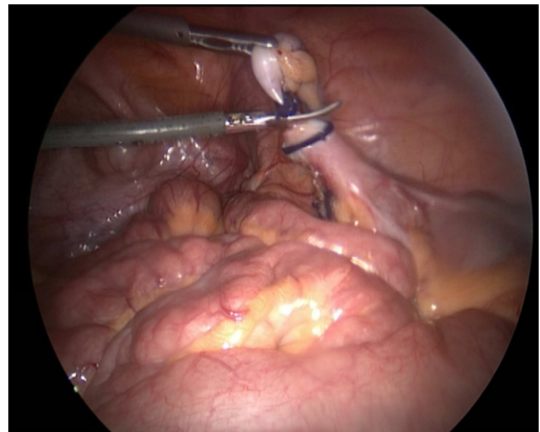
**Figure 1.** Ligation of mesoappendix using harmonic scalpel.



**Figure 2.** Preparing absorbable endoclip near appendicular stump.



**Figure 3.** Endoclip at the base of the appendix.



**Figure 4.** Cutting appendix between proximal and distal endoclips.

### 4. Results

Between October 2014 to October 2015, 40 patients were included in our study. 24 (60%) patients were female and 16 (40%) were male. Their ages ranged between 18 and 42 years old [mean age was  $29.65 \pm 8.11630$  years].

The mean operative time was  $29.6250 \pm 5.94284$  minute. The mean postoperative hospital stay was  $1 \pm 0.00000$  day. The endo clips were applied in 32 patients (80%) and was failed in 8 patients either due to too large diameter of the appendix base in 6 patients or inflamed caecum in 2 patients. In those 8 patients endoloop ligation for appendicular stump closure was done. None of the patients converted to open appendectomy. No intraoperative complications. In all cases, no leak from the appendicular stump could be detected. Superficial wound infections were found in two patients (5%) which respond to oral antibiotic therapy, intra-abdominal abscesses in one (2.5%) drainage under ultrasonography was done, no mortality was detected in this study.

### 5. Discussion

Laparoscopic appendectomy has many advantages such as less postoperative pain and early recovery of bowel function [11].

During laparoscopic appendectomy many techniques used for closure of the appendicular stump such as intra-abdominal knotting, extracorporeal knotting,

ENDOLOOP® Ligature (ETHICON; New Jersey, USA), endoclip, polymeric clip, and staplers [12]. Each techniques have advantages and disadvantages either related to the material used or the technique [13]. Safety, application comfort, foreign body effects of the materials, operating time, and etc. are t key points defining the variety of the methods. The ideal method for closure of appendicular stump should be the fast and safe and not associated with no long term complications. For a long time Endo-loops have been used in laparoscopic appendectomy to divide the mesoappendix and close the appendicular stump. In comparison to intra-corporeal knotting technique, ENDOLOOP® Ligature (ETHICON; New Jersey, USA) is relatively easier and faster [14]. Polymeric clips that used to seal the vessels in laparoscopic surgery was also used for closure of appendicular stump during laparoscopic appendectomy [12]. The advantage of the clip that it has a lock at its tip allowing a very secure clipping. In 2011 Delibegovic et al studied the application of polymeric endoclip and endloop in a rat model as regard their tissue reactions in the intestine [15]. The results of their study revealed that both materials had acceptable tissue foreign body reaction but the tissue reaction degree of the polymeric clips were slightly less than endo-loops. Another study by Hanssen et al reported that the use of polymeric clips has been found to be safe and effective [16].

In this study the use of absorbable polydioxnon endoclips in laproscopic appendectomy was evaluated. One clip was applied to the appendix base and another to the distal part which was removed. Appendix stumps with a diameter of up to 10mm could be safely closed. Due to the design of the clip as it has a lock at its distal end the use of one clip on each side was sufficient. Many studies reported the usage of one or two clips that placed onto the appendix stump. The largest recommended diameter of the appendicular stump that can be safely closed with this clip is 10 mm [17]. In this study The endo clips were applied in 32out of 40 patients (80%). Chang et al., in 2013 reported success rate 92.8% the haemo-lock clips was applied in 39 out of 42 patients [18].

In this study none of the cases required conversion to open appendectomy although some study reported arate of conversion from 10 to 39.7% [19].

Surgical site infection (wound and intra-abdominal) was used to evaluate the efficacy and safety of laproscopic appendectomy. In this study, the authors reported that the rate of superficial wound infections was (5%) all cases responded to oral antibiotic and intra-abdominal abscesses observed in one case (2.5%) which drained using ultrasonography. These results were comparable to the result that reported by Markides et al in 2010. They reported that (4.2%) had wound infection and 5.9% had intra-abdominal infection [3]. No complications required re-operation in this study. Also the study done by Hue et al., comparing ENDOLOOP® Ligature (ETHICON; New Jersey, USA) and polymeric clip for closure of the appendicular stump during laparoscopic appendectomy [20], Reported that no statistically significant difference between these two methods regarding the

feasibility and safety of the operation but The operative time was found to be significantly shorter. Unfortunately our study not comparative one. it also include a small number of patient. we hope to conduct a large randomized controlled study including alarge number of patients from our developing country with a special emphasize on cost effectiveness.

## 6. Conclusions

The results suggest that the polydioxnone endo clip is a safe and effective option in securing the appendicular stump in laparoscopic appendectomy.

## Conflict of Interest

The authors declare that hedoesn'thave any conflict of interest.

## References

- [1] Chung RS, Rowland DY, Li P, Diaz J (.1999) A meta-analysis of randomized controlled trials of laparoscopic versus conventional appendectomy. *Am J Surg*; 177: 250-6.
- [2] Wei B, Qi CL, Chen TF, Zheng ZH, Huang JL, Hu BG, Wei HB (2011;). Laparoscopic versus open appendectomy for acute appendicitis: a metaanalysis. *Surg Endosc*. 25: 1199-208.
- [3] Markides G, Subar D, Riyad K(2010). Laparoscopic versus open appendectomy in adults with complicated appendicitis: systematic review and meta-analysis. *World J Surg*, 34: 2026-40.
- [4] Markar SR, Penna M, Harris A (2014). Laparoscopic approach to appendectomy reduces the incidence of short- and long-term post-operative bowel obstruction: systematic review and pooled analysis. *J Gastro Intest Surg*, 18: 1683-92.
- [5] Semm K (1983). Endoscopicappendectomy. *Endoscopy*. 15:59-64.
- [6] Beldi G, Vorburger SA, Bruegger LE, Kocher T, Inderbitzin D, Candinas D (2006): Analysis of stapling versus endoloops in appendiceal stump closure. *Br J Surg*, 93(11):1390-1393.
- [7] Roviario GC, Vergani C, Varoli F, Francese M, Caminiti R, Maciocco M (2006): Videolaparoscopic appendectomy: the current outlook. *Surg Endosc*. 20:1526-1530.
- [8] Alis H, Gonenc M, Deniztas C, Kapan S, Turhan NA(2012): Metal endoclips for the closure of the appendiceal stump in laparoscopic appendectomy. *Tech Coloproctol*, 16(2):139-141.
- [9] Partecke LI, Kessler W, von BW, Diedrich S, Heidecke CD, Patrzyk M (2010) Laparoscopic appendectomy using a single polymeric clip to close the appendicular stump. *LangenbecksArch Surg* 395:1077-1082
- [10] Delibegovic S, Matovic E (2009) Hem-o-lok plastic clips in securing of the base of the appendix during laparoscopic appendectomy. *Surg Endosc* 23:2851-2854.

- [11] Guller U, Hervey S, Purves H, Muhlbaier LH, Peterson ED, Eubanks S, Pietrobon R (2004) Laparoscopic versus open appendectomy: outcomes comparison based on a large administrative database. *Ann Surg* 239: 43–52.
- [12] Gomes CA, Nunes TA, Soares C Jr, Gomes CC(2012). The appendiceal stump closure during laparoscopy: historical, surgical, and future perspectives. *Surg Laparosc Endosc Percutan Tech*. 22: 1-4.
- [13] Gorter RR, Heij HA, Eker HH, Kazemier G(2014). Laparoscopic appendectomy: State of the art. Tailored approach to the application of laparoscopic appendectomy? *Best Pract Res Clin Gastroenterol*. 28: 211-24.
- [14] Beldi G, Muggli K, Helbling C, Schlumpf R(2004). Laparoscopic appendectomy using endoloops: a prospective, randomized clinical trial. *Surg Endosc*. 18: 749-50.
- [15] Delibegović S, Iljazović E, Katica M, Koluh A(2011). Tissue reaction to absorbable endoloop, nonabsorbable titanium staples, and polymer Hem-o-lok clip after laparoscopic appendectomy. *JSLs* ; 15: 70-6.
- [16] Hanssen A, Plotnikov S, Dubois R(2007). Laparoscopic appendectomy using a polymeric clip to close the appendicular stump. *JSLs*; 11: 59-62.
- [17] Sajid MS, Rimple J, Cheek E, Baig MK (2009) Use of endo-GIA versus endo-loop for securing the appendicular stump in laparoscopic appendectomy: a systematic review. *Surg Laparosc Endosc Percutan Tech* 19:11–15.
- [18] Partecke LI, Kessler W, von BW, Diedrich S, Heidecke CD, Patrzyk M (2010) Laparoscopic appendectomy using a single polymeric clip to close the appendicular stump. *Langenbecks Arch Surg* 395: 1077–1082.
- [19] Delibegovic S, Matovic E (2009) Hem-o-lok plastic clips in securing of the base of the appendix during laparoscopic appendectomy. *Surg Endosc* 23: 2851–2854.
- [20] Hue CS, Kim JS, Kim KH, Nam SH, Kim KW(2013). The usefulness and safety of Hem-o-lok clips for the closure of appendicular stump during laparoscopic appendectomy. *J Korean Surg Soc*; 84: 27-32.